

# Protocol for the Examination of Specimens From Patients With Primary Carcinoma of the Colon and Rectum

**Low-grade neuroendocrine tumors (carcinoid tumors) are not included.**

---

**Based on AJCC/UICC TNM, 7th edition**

Protocol web posting date: January 2016

## Procedures

- Excisional Biopsy (Polypectomy)
- Local Excision (Transanal Disk Excision)
- Colectomy (Total, Partial, or Segmental Resection)
- Rectal Resection (Low Anterior Resection or Abdominoperineal Resection)

## Authors

Laura H. Tang, MD, PhD\*

Department of Pathology, Memorial Sloan-Kettering Cancer Center, New York, NY

Jordan Berlin, MD

Department of Medicine, Vanderbilt University Medical Center, Nashville, TN

Philip Branton, MD

Department of Pathology, Inova Fairfax Hospital, Falls Church, VA

Lawrence J. Burgart, MD

Allina Laboratories, Abbott Northwestern Hospital, Minneapolis, MN

David K. Carter, MD

Department of Pathology, St. Mary's/Duluth Clinic Health System, Duluth, MN

Patrick Fitzgibbons, MD

Department of Pathology, St. Jude Medical Center, Fullerton, CA

Wendy L. Frankel, MD

Department of Pathology, Ohio State University Medical Center, Columbus, OH

Kevin C. Halling, MD, PhD

Department of Laboratory Medicine and Pathology, Mayo Clinic, Rochester, MN

John Jessup, MD

Division of Cancer Treatment and Diagnosis, National Cancer Institute, Bethesda, MD

Sanjay Kakar, MD

Department of Pathology, University of California San Francisco and the Veterans Affairs Medical Center, San Francisco, CA

Bruce Minsky, MD

Department of Radiation Oncology, University of Chicago, Chicago, IL

Raouf Nakhleh, MD

Department of Pathology, St. Luke's Hospital, Jacksonville, FL

Kay Washington, MD, PhD

Department of Pathology, Vanderbilt University Medical Center, Nashville, TN

Carolyn C. Compton, MD, PhD†

Critical Path Institute, Tucson, AZ

For the Members of the Cancer Committee, College of American Pathologists

\*Denotes primary author. † Denotes senior author. All other contributing authors are listed alphabetically.

**Previous lead contributors:** Donald E. Henson, MD; Robert V.P. Hutter, MD; Leslie H. Sobin, MD; Harold E. Bowman, MD

© 2016 College of American Pathologists (CAP). All rights reserved.

The College does not permit reproduction of any substantial portion of these protocols without its written authorization. The College hereby authorizes use of these protocols by physicians and other health care providers in reporting on surgical specimens, in teaching, and in carrying out medical research for nonprofit purposes. This authorization does not extend to reproduction or other use of any substantial portion of these protocols for commercial purposes without the written consent of the College.

The CAP also authorizes physicians and other health care practitioners to make modified versions of the Protocols solely for their individual use in reporting on surgical specimens for individual patients, teaching, and carrying out medical research for non-profit purposes.

The CAP further authorizes the following uses by physicians and other health care practitioners, in reporting on surgical specimens for individual patients, in teaching, and in carrying out medical research for non-profit purposes: (1) **Dictation** from the original or modified protocols for the purposes of creating a text-based patient record on paper, or in a word processing document; (2) **Copying** from the original or modified protocols into a text-based patient record on paper, or in a word processing document; (3) The use of a **computerized system** for items (1) and (2), provided that the protocol data is stored intact as a single text-based document, and is not stored as multiple discrete data fields.

Other than uses (1), (2), and (3) above, the CAP does not authorize any use of the Protocols in electronic medical records systems, pathology informatics systems, cancer registry computer systems, computerized databases, mappings between coding works, or any computerized system without a written license from the CAP.

Any public dissemination of the original or modified protocols is prohibited without a written license from the CAP.

The College of American Pathologists offers these protocols to assist pathologists in providing clinically useful and relevant information when reporting results of surgical specimen examinations of surgical specimens. The College regards the reporting elements in the "Surgical Pathology Cancer Case Summary" portion of the protocols as essential elements of the pathology report. However, the manner in which these elements are reported is at the discretion of each specific pathologist, taking into account clinician preferences, institutional policies, and individual practice.

The College developed these protocols as an educational tool to assist pathologists in the useful reporting of relevant information. It did not issue the protocols for use in litigation, reimbursement, or other contexts. Nevertheless, the College recognizes that the protocols might be used by hospitals, attorneys, payers, and others. Indeed, effective January 1, 2004, the Commission on Cancer of the American College of Surgeons mandated the use of the required data elements of the protocols as part of its Cancer Program Standards for Approved Cancer Programs. Therefore, it becomes even more important for pathologists to familiarize themselves with these documents. At the same time, the College cautions that use of the protocols other than for their intended educational purpose may involve additional considerations that are beyond the scope of this document.

The inclusion of a product name or service in a CAP publication should not be construed as an endorsement of such product or service, nor is failure to include the name of a product or service to be construed as disapproval.

## CAP Colon and Rectum Protocol Revision History

---

### Version Code

The definition of version control and an explanation of version codes can be found at [www.cap.org](http://www.cap.org) (search: cancer protocol terms).

**Version:** ColonRectum 3.4.0.0

### Summary of Changes

The following changes have been made since the October 2013 release.

#### Excisional Biopsy (Polypectomy)

The following data elements were modified:

- Polyp Size
- Size of Invasive Carcinoma
- Histologic Type
- Lymph-Vascular Invasion
- Type of Polyp in Which Invasive Carcinoma Arose
- Perineural Invasion
- Distant Metastasis (changed to required only if confirmed pathologically)

#### Resection, Including Transanal Disk Excision of Rectal Neoplasms

The following data elements were modified:

- Procedure
- Tumor Site
- Tumor Location
- Tumor Size
- Histologic Type
- Microscopic Tumor Extension
- Margins
- Treatment Effect
- Lymph-Vascular Invasion
- Perineural Invasion
- Tumor Deposits
- Type of Polyp in Which Invasive Carcinoma Arose
- Perineural Invasion
- Distant Metastasis (changed to required only if confirmed pathologically)
- Additional Pathologic Findings

**Surgical Pathology Cancer Case Summary**

---

Protocol web posting date: January 2016

**COLON AND RECTUM: Excisional Biopsy (Polypectomy)**

Select a single response unless otherwise indicated.

**Tumor Site (Note A)**

- Cecum  
 Right (ascending) colon  
 Hepatic flexure  
 Transverse colon  
 Splenic flexure  
 Left (descending) colon  
 Sigmoid colon  
 Rectum  
 Other (specify): \_\_\_\_\_  
 Not specified

**+ Specimen Integrity**

- Intact  
 Fragmented

**+ Polyp Size**

- Greatest dimension: \_\_\_\_ cm  
 Additional dimensions: \_\_\_\_ x \_\_\_\_ cm  
 Cannot be determined (explain): \_\_\_\_\_

**+ Polyp Configuration**

- Pedunculated with stalk  
     + Stalk length: \_\_\_\_ cm  
 Sessile

**Size of Invasive Carcinoma**

- Greatest dimension: \_\_\_\_ cm  
 Additional dimensions: \_\_\_\_ x \_\_\_\_ cm  
 Cannot be determined (explain): \_\_\_\_\_

**Histologic Type (select all that apply) (Note B)**

- Adenocarcinoma  
 Mucinous adenocarcinoma  
 Signet-ring cell carcinoma  
 Medullary carcinoma  
 High-grade neuroendocrine carcinoma  
      Large cell neuroendocrine carcinoma  
      Small cell neuroendocrine carcinoma  
 Squamous cell carcinoma  
 Adenosquamous carcinoma  
 Micropapillary carcinoma  
 Serrated adenocarcinoma  
 Spindle cell carcinoma

+ Data elements preceded by this symbol are not required. However, these elements may be clinically important but are not yet validated or regularly used in patient management.

- Mixed adenoneuroendocrine carcinoma
- Undifferentiated carcinoma
- Other (specify): \_\_\_\_\_
- Carcinoma, type cannot be determined

**Histologic Grade (Note C)**

- Not applicable
- Cannot be determined
- Low grade (well-differentiated to moderately differentiated)
- High grade (poorly differentiated to undifferentiated)

**Microscopic Tumor Extension (Note D)**

- Cannot be determined

Invasion (deepest):

- Lamina propria
- Muscularis mucosae
- Submucosa
- Muscularis propria

**Margins (select all that apply)**

Deep Margin (Stalk Margin)

- Cannot be assessed
- Uninvolved by invasive carcinoma  
Distance of invasive carcinoma from margin: \_\_\_ mm or \_\_\_ cm
- Involved by invasive carcinoma

Mucosal Margin (required only if applicable)

- Cannot be assessed
- Uninvolved by invasive carcinoma
- Involved by invasive carcinoma
- Involved by adenoma

**Lymph-Vascular Invasion (select all that apply) (Notes D and E)**

- Not identified
- Present
  - +  Small vessel lymphovascular invasion
  - +  Large vessel (venous) invasion
    - +  Intramural
    - +  Extramural
- Cannot be determined

**+ Type of Polyp in Which Invasive Carcinoma Arose (Note F)**

- +  Tubular adenoma
- +  Villous adenoma
- +  Tubulovillous adenoma
- +  Traditional serrated adenoma
- +  Sessile serrated adenoma
- +  Hamartomatous polyp
- +  Other (specify): \_\_\_\_\_

**+ Additional Pathologic Findings (select all that apply)**

- + \_\_\_ None identified
- + \_\_\_ Inflammatory bowel disease
  - + \_\_\_ Active
  - + \_\_\_ Quiescent
- + \_\_\_ Other (specify): \_\_\_\_\_

**+ Ancillary Studies**

*Note:* For reporting molecular testing and immunohistochemistry for mismatch repair proteins, and for other cancer biomarker testing results, the CAP Colorectal Biomarker Template should be used. Pending biomarker studies should be listed in the Comments section of this report.

**+ Comment(s)**

**Surgical Pathology Cancer Case Summary**

---

Protocol web posting date: January 2016

**COLON AND RECTUM: Resection, Including Transanal Disk Excision of Rectal Neoplasms****Select a single response unless otherwise indicated.****Specimen (select all that apply) (Note A)**

- Terminal ileum
- Cecum
- Appendix
- Ascending colon
- Transverse colon
- Descending colon
- Sigmoid colon
- Rectum
- Anus
- Other (specify): \_\_\_\_\_
- Not specified

**Procedure**

- Right hemicolectomy
- Transverse colectomy
- Left hemicolectomy
- Sigmoidectomy
- Low anterior resection
- Total abdominal colectomy
- Abdominoperineal resection
- Transanal disk excision (local excision)
- Endoscopic mucosal resection
- Other (specify): \_\_\_\_\_
- Not specified

**Tumor Site (select all that apply) (Note A)**

- Cecum
- Right (ascending) colon
- Hepatic flexure
- Transverse colon
- Splenic flexure
- Left (descending) colon
- Sigmoid colon
- Rectosigmoid
- Rectum
- Ileocecal valve
- Colon, not otherwise specified
- Cannot be determined (explain): \_\_\_\_\_

**+ Tumor Location (applicable only to rectal primaries) (Note A)**

- +  Tumor is located entirely above peritoneal reflection
- +  Tumor is located entirely below the peritoneal reflection
- +  Tumor straddles the anterior peritoneal reflection
- +  Not specified

+ Data elements preceded by this symbol are not required. However, these elements may be clinically important but are not yet validated or regularly used in patient management.

**Tumor Size**

Greatest dimension: \_\_\_ cm

+ Additional dimensions: \_\_\_ x \_\_\_ cm

\_\_\_ Cannot be determined (explain): \_\_\_\_\_

**Macroscopic Tumor Perforation (Note G)**

\_\_\_ Present

\_\_\_ Not identified

\_\_\_ Cannot be determined

**+ Macroscopic Intactness of Mesorectum (Note H)**

+ \_\_\_ Not applicable

+ \_\_\_ Complete

+ \_\_\_ Near complete

+ \_\_\_ Incomplete

+ \_\_\_ Cannot be determined

**Histologic Type (select all that apply) (Note B)**

\_\_\_ Adenocarcinoma

\_\_\_ Mucinous adenocarcinoma

\_\_\_ Signet-ring cell carcinoma

\_\_\_ Medullary carcinoma

\_\_\_ High-grade neuroendocrine carcinoma

\_\_\_ Large cell neuroendocrine carcinoma

\_\_\_ Small cell neuroendocrine carcinoma

\_\_\_ Squamous cell carcinoma

\_\_\_ Adenosquamous carcinoma

\_\_\_ Undifferentiated carcinoma

\_\_\_ Other (specify): \_\_\_\_\_

\_\_\_ Carcinoma, type cannot be determined

**Histologic Grade (Note C)**

\_\_\_ Not applicable

\_\_\_ Cannot be assessed

\_\_\_ Low grade (well-differentiated to moderately differentiated)

\_\_\_ High grade (poorly differentiated to undifferentiated)

\_\_\_ Other (specify): \_\_\_\_\_

**+ Histologic Features Suggestive of Microsatellite Instability (Note I)**+ Intratumoral Lymphocytic Response (tumor-infiltrating lymphocytes)

+ \_\_\_ None

+ \_\_\_ Mild to moderate (0-2 per high-power [X400] field)

+ \_\_\_ Marked (3 or more per high-power field)

+ Peritumor Lymphocytic Response (Crohn-like response)

+ \_\_\_ None

+ \_\_\_ Mild to moderate

+ \_\_\_ Marked

+ Tumor Subtype and Differentiation (select all that apply)

+ \_\_\_ Mucinous tumor component (specify percentage: \_\_\_\_%)

+ \_\_\_ Medullary tumor component

+ \_\_\_ High histologic grade (poorly differentiated)



**Microscopic Tumor Extension**

- Cannot be assessed
- No evidence of primary tumor
- No invasion (high-grade dysplasia/intraepithelial carcinoma)
- Tumor invades lamina propria/muscularis mucosae (intramucosal carcinoma)
- Tumor invades submucosa
- Tumor invades muscularis propria
- Tumor invades through the muscularis propria into the subserosal adipose tissue or the nonperitonealized pericolic or perirectal soft tissues but does not extend to the serosal surface
- Tumor penetrates to the surface of the visceral peritoneum (serosa)
- Tumor is adherent to other organs or structures (specify: \_\_\_\_\_)
- Tumor directly invades adjacent structures (specify: \_\_\_\_\_)
- Tumor penetrates to the surface of the visceral peritoneum (serosa) *and* directly invades adjacent structures (specify: \_\_\_\_\_)

**Margins (select all that apply) (Note J)**

If all margins uninvolved by invasive carcinoma:

Distance of invasive carcinoma from closest margin: \_\_\_ mm or \_\_\_ cm  
 Specify margin: \_\_\_\_\_

*For resection specimens only:*

Proximal Margin

- Cannot be assessed
- Uninvolved by invasive carcinoma  
 + Distance of tumor from margin: \_\_\_ mm or \_\_\_ cm
- Involved by invasive carcinoma

Distal Margin

- Cannot be assessed
- Uninvolved by invasive carcinoma  
 Distance of tumor from margin (required only for rectal tumors): \_\_\_ mm or \_\_\_ cm
- Involved by invasive carcinoma

Circumferential (Radial) Margin

- Not applicable
- Cannot be assessed
- Uninvolved by invasive carcinoma  
 Distance of tumor from margin (required only for rectal tumors): \_\_\_ mm or \_\_\_ cm
- Involved by invasive carcinoma (tumor present 0-1 mm from margin)

Mesenteric Margin

- Not applicable
- Cannot be assessed
- Uninvolved by invasive carcinoma  
 + Distance of tumor from margin: \_\_\_ mm or \_\_\_ cm
- Involved by invasive carcinoma (tumor present 0-1 mm from margin)

Other Margin(s) (required only if applicable)

- Specify margin(s): \_\_\_\_\_
- Cannot be assessed
  - Uninvolved by invasive carcinoma
  - Involved by invasive carcinoma

+ Data elements preceded by this symbol are not required. However, these elements may be clinically important but are not yet validated or regularly used in patient management.

*For transanal disk excision specimens only:*

**Deep Margin**

- Cannot be assessed  
 Uninvolved by invasive carcinoma  
     + Distance of tumor from margin: \_\_\_ mm or \_\_\_ cm  
 Involved by invasive carcinoma

**Mucosal Margin**

- Cannot be assessed  
 Uninvolved by invasive carcinoma  
     Distance of invasive carcinoma from closest mucosal margin: \_\_\_ mm or \_\_\_ cm  
     + Specify location (eg, o'clock position), if possible: \_\_\_\_\_  
 Involved by invasive carcinoma  
     + Specify location (eg, o'clock position), if possible: \_\_\_\_\_  
 Involved by high-grade dysplasia  
 Involved by intramucosal carcinoma

**Treatment Effect (applicable to carcinomas treated with neoadjuvant therapy) (select all that apply) (Note K)**

- No prior treatment  
 Present  
     +  No viable cancer cells (complete response, score 0)  
     +  Single cells or rare small groups of cancer cells (near complete response, score 1)  
     +  Residual cancer with evident tumor regression, but more than single cells or rare small groups of cancer cells (partial response, score 2)  
 Extensive residual cancer with no evident tumor regression (poor or no response, score 3)  
 Not known

**Lymph-Vascular Invasion (select all that apply) (Note E)**

- Not identified  
 Present  
 +  Small vessel lymph-vascular invasion  
 +  Large vessel (venous) invasion  
     +  Intramural  
     +  Extramural  
 Cannot be determined

**Perineural Invasion (Note E)**

- Not identified  
 Present  
 Cannot be determined

**Tumor Deposits (Note L)**

- Not identified  
 Present (specify number of deposits): \_\_\_\_  
 Cannot be determined

**+ Type of Polyp in Which Invasive Carcinoma Arose (Note F)**

- + \_\_\_ None identified
- + \_\_\_ Tubular adenoma
- + \_\_\_ Villous adenoma
- + \_\_\_ Tubulovillous adenoma
- + \_\_\_ Traditional serrated adenoma
- + \_\_\_ Sessile serrated adenoma
- + \_\_\_ Serrated polyp, unclassified
- + \_\_\_ Hamartomatous polyp
- + \_\_\_ Other (specify): \_\_\_\_\_

**Pathologic Staging (pTNM) (Note M)**TNM Descriptors (required only if applicable) (select all that apply)

- \_\_\_ m (multiple primary tumors)
- \_\_\_ r (recurrent)
- \_\_\_ y (posttreatment)

Primary Tumor (pT)

- \_\_\_ pTX: Cannot be assessed
- \_\_\_ pT0: No evidence of primary tumor
- \_\_\_ pTis: Carcinoma in situ, intraepithelial (no invasion of lamina propria)
- \_\_\_ pTis: Carcinoma in situ, invasion of lamina propria/muscularis mucosae
- \_\_\_ pT1: Tumor invades submucosa
- \_\_\_ pT2: Tumor invades muscularis propria
- \_\_\_ pT3: Tumor invades through the muscularis propria into pericolorectal tissues
- \_\_\_ pT4a: Tumor penetrates the visceral peritoneum
- \_\_\_ pT4b: Tumor directly invades or is adherent to other organs or structures

Regional Lymph Nodes (pN)

- \_\_\_ pNX: Cannot be assessed
- \_\_\_ pN0: No regional lymph node metastasis
- \_\_\_ pN1a: Metastasis in 1 regional lymph node
- \_\_\_ pN1b: Metastasis in 2 to 3 regional lymph nodes
- \_\_\_ pN1c: Tumor deposit(s) in the subserosa, or non-peritonealized pericolic or perirectal tissues without regional lymph node metastasis
- \_\_\_ pN2a: Metastasis in 4 to 6 regional lymph nodes
- \_\_\_ pN2b: Metastasis in 7 or more regional lymph nodes

\_\_\_ No nodes submitted or found

*Number of Lymph Nodes Examined*

Specify: \_\_\_

\_\_\_ Number cannot be determined (explain): \_\_\_\_\_

*Number of Lymph Nodes Involved*

Specify: \_\_\_

\_\_\_ Number cannot be determined (explain): \_\_\_\_\_

Distant Metastasis (pM) (required only if confirmed pathologically in this case)

- \_\_\_ pM1: Distant metastasis
- \_\_\_ pM1a: Metastasis to single organ or site (eg, liver, lung, ovary, nonregional lymph node)
- \_\_\_ pM1b: Metastasis to more than 1 organ/site or to the peritoneum

Specify site(s), if known: \_\_\_\_\_

**+ Additional Pathologic Findings (select all that apply)**

- +  None identified
- +  Adenoma(s)
- +  Chronic ulcerative proctocolitis
- +  Crohn disease
- +  Diverticulosis
- +  Dysplasia arising in inflammatory bowel disease
- +  Other polyps (type[s]): \_\_\_\_\_
- +  Other (specify): \_\_\_\_\_

**+ Ancillary Studies**

*Note:* For reporting molecular testing and immunohistochemistry for mismatch repair proteins, and for other cancer biomarker testing results, the CAP Colorectal Biomarker Template should be used. Pending biomarker studies should be listed in the Comments section of this report.

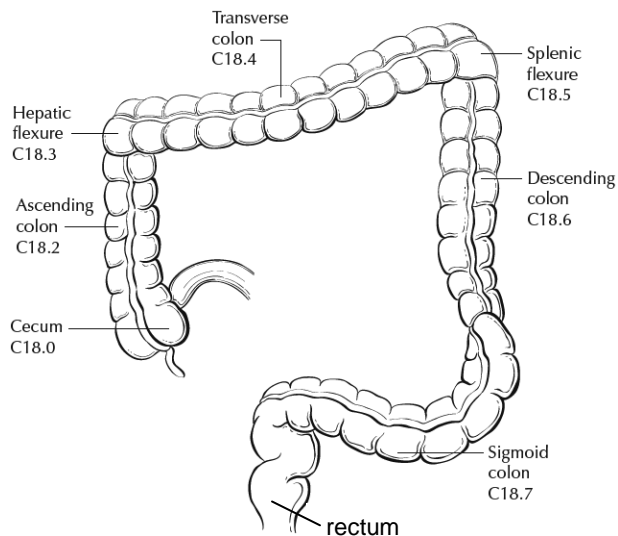
**+ Comment(s)**

## Explanatory Notes

### A. Anatomic Sites

The protocol applies to all carcinomas arising in the colon and rectum.<sup>1</sup> It excludes carcinomas of the vermiform appendix and low-grade neuroendocrine neoplasms (carcinoid tumors).

The colon is divided as shown in Figure 1. The right colon is subdivided into the cecum and the ascending colon.<sup>2</sup> The left colon is subdivided into the descending colon and sigmoid colon (see Table 1).<sup>1</sup>

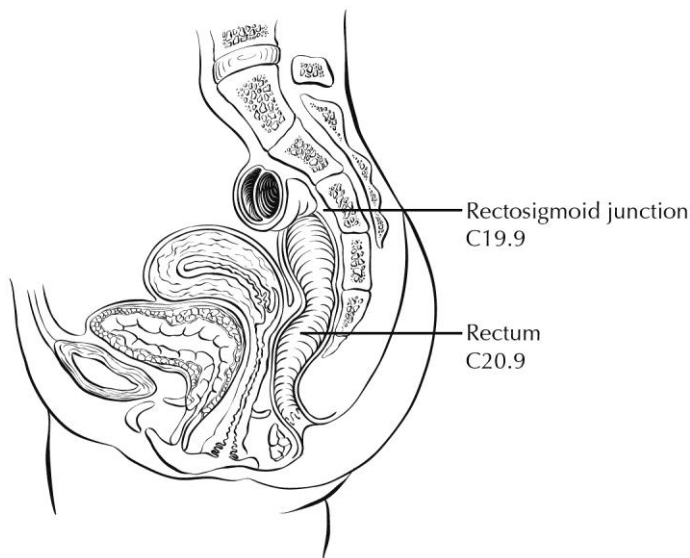


**Figure 1.** Anatomic subsites of the colon. Used with permission of the American Joint Committee on Cancer (AJCC), Chicago, Ill. The original source for this material is the *AJCC Cancer Staging Atlas* (2006) edited by Greene et al<sup>2</sup> and published by Springer Science and Business Media, LLC, [www.springerlink.com](http://www.springerlink.com).

**Table 1. Anatomic Subsites of the Colon and Rectum**

Site	Relationship to Peritoneum (see Note J)	Dimensions (approximate)
Cecum	Entirely covered by peritoneum	6 x 9 cm
Ascending colon	Retroperitoneal; posterior surface lacks peritoneal covering; lateral and anterior surfaces covered by visceral peritoneum (serosa)	15-20 cm long
Transverse colon	Intraperitoneal; has mesentery	Variable
Descending colon	Retroperitoneal; posterior surface lacks peritoneal covering; lateral and anterior surfaces covered by visceral peritoneum (serosa)	10-15 cm long
Sigmoid colon	Intraperitoneal; has mesentery	Variable
Rectum	Upper third covered by peritoneum on anterior and lateral surfaces; middle third covered by peritoneum only on anterior surface; lower third has no peritoneal covering	12 cm long

The transition from sigmoid to rectum is marked by the fusion of the tenia coli of the sigmoid to form the circumferential longitudinal muscle of the rectal wall approximately 12 to 15 cm from the dentate line. The rectum is defined clinically as the distal large intestine commencing opposite the sacral promontory and ending at the anorectal ring, which corresponds to the proximal border of the puborectalis muscle palpable on digital rectal examination<sup>1</sup> (Figure 2). When measuring below with a rigid sigmoidoscope, it extends 16 cm from the anal verge.



**Figure 2.** Anatomic subsites of the rectum. Used with permission of the American Joint Committee on Cancer (AJCC), Chicago, Ill. The original source for this material is the *AJCC Cancer Staging Atlas* (2006) edited by Greene et al<sup>2</sup> and published by Springer Science and Business Media, LLC, [www.springerlink.com](http://www.springerlink.com).

Tumors located at the border between 2 subsites of the colon (eg, cecum and ascending colon) are registered as tumors of the subsite that is more involved. If 2 subsites are involved to the same extent, the tumor is classified as an "overlapping" lesion.

A tumor is classified as rectal if its inferior margin lies less than 16 cm from the anal verge or if any part of the tumor is located at least partly within the supply of the superior rectal artery.<sup>3</sup> The rectum commences at the sacral promontory, and the junction of sigmoid colon and rectum is anatomically marked by fusion of tenia coli to form the circumferential longitudinal muscle of the rectal wall. Intraoperatively, the rectosigmoid junction corresponds to the sacral promontory. A tumor is classified as rectosigmoid when differentiation between rectum and sigmoid according to the previously mentioned guidelines is not possible.<sup>4</sup>

Anteriorly, the peritoneal reflection is located at the junction of middle and lower third of the rectum, while laterally, it is located at the junction of upper and middle third of the rectum. Posteriorly, the reflection is located higher and most of the posterior rectum does not have a serosal covering.

(a) Whether an adenocarcinoma located in the rectum has a circumferential resection (radial) margin (CRM) or a peritoneal (serosal) surface (with no true circumferential resection margin) depends on its location in relation to the peritoneal reflections. Tumors below the anterior peritoneal reflection will have a 360-degree CRM, while those above it may have a CRM or a peritoneal (serosal) surface, or both, depending on the precise location.

(b) Neoadjuvant therapy and mesorectal excision are considered standard of care for rectal adenocarcinomas "below the anterior peritoneal reflection," while the opinions about use of these modalities vary about rectal adenocarcinomas located above the anterior peritoneal reflection. Conservative options like transanal disc excisions are often considered for location "below the anterior peritoneal reflection." In these contexts, the peritoneal reflection refers to the junction of upper and middle third of the rectum; there is ongoing debate in the surgical literature about the concept of peritoneal reflection.<sup>5</sup> If information about tumor location with respect to the peritoneal reflection is included in the report, the aspect of rectum in question (posterior, lateral, anterior) should also be noted.

**B. Histologic Types**

For consistency in reporting, the histologic classification proposed by the World Health Organization (WHO) is recommended and is shown below.<sup>6</sup>

**WHO Classification of Colorectal Carcinoma**

Adenocarcinoma

Mucinous (colloid) adenocarcinoma (greater than 50% mucinous)

Signet-ring cell carcinoma (greater than 50% signet-ring cells)<sup>#</sup>

Squamous cell carcinoma

Adenosquamous carcinoma

Medullary carcinoma<sup>##</sup>

Cribriform comedo-type, micropapillary and serrated adenocarcinomas as well as spindle cell carcinoma

Neuroendocrine carcinoma

Large cell neuroendocrine carcinoma

Small cell neuroendocrine carcinoma<sup>#</sup>

Mixed adenoneuroendocrine carcinoma

Undifferentiated carcinoma<sup>#</sup>

<sup>#</sup> By convention, signet-ring cell carcinomas, small cell carcinomas, and undifferentiated carcinomas are high grade (see Note C). The only histologic types of colorectal carcinoma that have been shown to have adverse prognostic significance independent of stage are signet-ring cell carcinoma<sup>7</sup> and small cell carcinoma (high-grade neuroendocrine carcinoma).<sup>8</sup>

<sup>##</sup> Medullary carcinoma is a distinctive histologic type strongly associated with high levels of microsatellite instability (MSI-H), indicative of defects in normal DNA repair gene function. Medullary carcinoma may occur either sporadically<sup>9</sup> or in association with hereditary nonpolyposis colon cancer (HNPCC).<sup>10</sup> This tumor type is characterized by solid growth in nested, organoid, or trabecular patterns, with no immunohistochemical evidence of neuroendocrine differentiation. Medullary carcinomas are also characterized by numerous tumor infiltrating lymphocytes (see Note I).

**C. Histologic Grade**

A number of grading systems for colorectal cancer have been suggested, but a single widely accepted and uniformly used standard for grading is lacking. Most systems stratify tumors into 3 or 4 grades as follows:

Grade 1	Well-differentiated
Grade 2	Moderately differentiated
Grade 3	Poorly differentiated
Grade 4	Undifferentiated

Despite a significant degree of interobserver variability,<sup>11</sup> histologic grade has repeatedly been shown by multivariate analysis to be a stage-independent prognostic factor.<sup>12</sup> Specifically, it has been demonstrated that high tumor grade is an adverse prognostic factor. It is noteworthy that in the majority of studies documenting the prognostic power of tumor grade, the number of grades has been collapsed to produce a 2-tiered stratification for data analysis as follows:

Low grade: Well differentiated and moderately differentiated

High grade: Poorly differentiated and undifferentiated

The widest variations in grading concern the stratification of low-grade tumors into well-differentiated or moderately differentiated categories, while interobserver variability in diagnosing high-grade carcinoma is relatively small. Therefore, in light of its proven prognostic value, relative simplicity, and reproducibility, a 2-tiered grading system for colorectal carcinoma (ie, low grade and high grade) is recommended. The following criteria for grading based on gland formation alone are suggested.<sup>13</sup>

Low grade = Greater than or equal to 50% gland formation

High grade = Less than 50% gland formation

#### D. Carcinoma in an Adenomatous Polyp: Microscopic Tumor Extension and High-Risk Features

Colorectal adenomas containing invasive adenocarcinoma that extends through the muscularis mucosae into the submucosa have been defined as *malignant polyps*.<sup>14</sup> This term encompasses cases in which the entire polyp head is replaced by carcinoma and adenomas with focal malignancy, but the definition excludes adenomas with high-grade dysplasia (intraepithelial carcinoma) or intramucosal carcinoma (invasive carcinoma limited to the lamina propria or invading no deeper than the muscularis mucosae), because these polyps possess negligible biological potential for metastasis<sup>15</sup> (see Tis in Note M).

Malignant polyps removed by endoscopic polypectomy require evaluation of histologic factors related to the risk of adverse outcome (ie, lymph node metastasis or local recurrence from residual malignancy) following polypectomy.<sup>14,16</sup> Factors shown to have independent prognostic significance and are important in determining the need for further surgical treatment include:

- Histologic grade
- Status of the resection margin
- Lymphatic/venous vessel involvement

An increased risk of adverse outcome has been shown to be associated with:

- High-grade carcinoma
- Tumor at or less than 1 mm from the resection margin
- Lymphatic/venous vessel involvement<sup>15</sup>

#### E. Lymph-Vascular and Perineural Invasion

It is recommended that small vessel vascular invasion should be reported separately from venous (large vessel) invasion. Small vessel invasion indicates tumor involvement of thin-walled structures lined by endothelium, without an identifiable smooth muscle layer or elastic lamina. Small vessels include lymphatics, capillaries, and postcapillary venules. Small vessel invasion is associated with lymph node metastasis and has been shown to be independent indicator of adverse outcome in several studies.<sup>17,18</sup> The higher prognostic significance of extramural small vessel invasion has been suggested,<sup>19</sup> but the importance of anatomic location in small vessel invasion (extramural or intramural) is not well defined.

Tumor involving endothelium-lined spaces with an identifiable smooth muscle layer or elastic lamina is considered venous (large vessel) invasion. Circumscribed tumor nodules surrounded by an elastic lamina on hematoxylin-eosin (H&E) or elastic stain are also considered venous invasion. Venous invasion can be extramural (beyond muscularis propria) or intramural (submucosa or muscularis propria). Extramural venous invasion has been demonstrated by multivariate analysis to be an independent adverse prognostic factor in multiple studies and is a risk factor for liver metastasis.<sup>19</sup> The significance of intramural venous invasion is less clear. Histologic features like tumor deposits adjacent to arterioles (“orphan arteriole” sign) and elongated tumor nodules extending into pericolonic fat from the muscularis propria (“protruding tongue” sign) can raise the suspicion for venous invasion.<sup>20</sup> Elastic stain can lead to 2- to 3-fold increase in the detection of venous invasion, and routine use of elastic stain has been recommended for all colorectal cancer resections.<sup>21</sup>

Perineural invasion has been shown to be independent indicator of poor prognosis.<sup>22-24</sup> While some series did not find perineural invasion to be a significant predictive factor in stage II disease,<sup>25,26</sup> many studies have confirmed its adverse effect on survival in stage II disease (santos, huh).<sup>18,27</sup> Extramural perineural invasion may have a greater adverse prognostic effect,<sup>23</sup> but the distinction between intramural and extramural perineural invasion has not been well studied.

#### F. Polyps

Distinction should be made between traditional serrated adenomas, which exhibit cytologic features of adenomas, and the newly described sessile serrated adenomas.<sup>28</sup> The sessile serrated adenoma may be the precursor lesion for colorectal carcinomas with high levels of microsatellite instability (MSI-H); they are more commonly found in the right colon and are characterized by serrated architecture with bulbous dilatation of deep crypts and lack of overt nuclear atypia, in most cases.



### G. Perforation

Tumor perforation is an uncommon complication of colorectal cancer, but one that is associated with a poor outcome, including high in-hospital mortality and morbidity.<sup>29</sup> Perforation of the uninvolved colon proximal to an obstructing tumor is also associated with high mortality because of generalized peritonitis and sepsis. Reported perforation rates range from 2.6% to 9%. Perforation is more likely to occur in older patients.

### H. Mesorectal Envelope

The quality of the surgical technique is a key factor in the success of surgical treatment for rectal cancer, both in the prevention of local recurrence and in long-term survival. Numerous studies have demonstrated that total mesorectal excision (TME) improves local recurrence rates and the corresponding survival by as much as 20%. This surgical technique entails precise sharp dissection within the areolar plane outside (lateral to) the visceral mesorectal fascia to remove the rectum. This plane encases the rectum, its mesentery, and all regional nodes and constitutes Waldeyer's fascia. High-quality TME surgery reduces local recurrence from 20% to 30%, to 8% to 10% or less, and increases 5-year survival from 48% to 68%.<sup>30,31</sup> Adjuvant therapy in the presence of a high-quality TME may further reduce local recurrence (from 8% to 2.6%).<sup>31</sup>

Pathologic evaluation of the resection specimen has been shown to be a sensitive means of assessing the quality of rectal surgery. It is superior to indirect measures of surgical quality assessment, such as perioperative mortality, rates of complication, number of local recurrences, and 5-year survival. It has been shown that macroscopic pathologic assessment of the completeness of the mesorectum of the specimen, scored as complete, partially complete, or incomplete, accurately predicts both local recurrence and distant metastasis.<sup>31</sup> Microscopic parameters, such as the status of the circumferential resection margin, the distance between the tumor and nearest circumferential margin (ie, "surgical clearance"), and the distance between the tumor and the closest distal margin, are all important predictors of local recurrence and may be affected by surgical technique. There is strong evidence that the status of the circumferential resection margin is a powerful predictor of local recurrence but is inconsistently evaluated and underreported.

The nonperitonealized surface of the fresh specimen is examined circumferentially, and the completeness of the mesorectum is scored as described below.<sup>31</sup> The entire specimen is scored according to the worst area.

#### Incomplete

- Little bulk to the mesorectum
- Defects in the mesorectum down to the muscularis propria
- After transverse sectioning, the circumferential margin appears very irregular

#### Nearly Complete

- Moderate bulk to the mesorectum
- Irregularity of the mesorectal surface with defects greater than 5 mm, but none extending to the muscularis propria
- No areas of visibility of the muscularis propria except at the insertion site of the levator ani muscles

#### Complete

- Intact bulky mesorectum with a smooth surface
- Only minor irregularities of the mesorectal surface
- No surface defects greater than 5 mm in depth
- No coning towards the distal margin of the specimen
- After transverse sectioning, the circumferential margin appears smooth

### I. Histopathologic Features Suggestive of Microsatellite Instability

Identification of MSI-H colorectal tumors is important, as mismatch repair deficiency may serve as a prognostic marker of patient outcome, as a predictive marker of response to chemotherapy, and as a screening tool for hereditary nonpolyposis colon cancer (HNPCC) (Lynch syndrome). Revised Bethesda guidelines for HNPCC detection recommend testing colorectal tumors for microsatellite instability under the following circumstances<sup>32</sup>:

- Colorectal cancer diagnosed in a patient who is younger than 50 years
- Presence of synchronous, metachronous, or other HNPCC-associated tumors (endometrial, stomach, ovarian, pancreas, ureter and renal pelvis, biliary tract, small bowel, and brain tumors and sebaceous adenomas and keratoacanthomas), regardless of age
- Colorectal cancer with MSI-H histology<sup>#</sup> in a patient who is younger than 60 years
- Colorectal cancer in 1 or more first-degree relatives with an HNPCC-related tumor, with 1 of the cancers being diagnosed in a person younger than 50 years
- Colorectal cancer diagnosed in 2 or more first- or second-degree relatives with HNPCC-related tumors, regardless of age

<sup>#</sup> MSI-H histologic features are defined as presence of tumor-infiltrating lymphocytes, Crohn-like lymphocytic reaction, mucinous/signet-ring cell differentiation, or medullary growth pattern.<sup>32</sup>

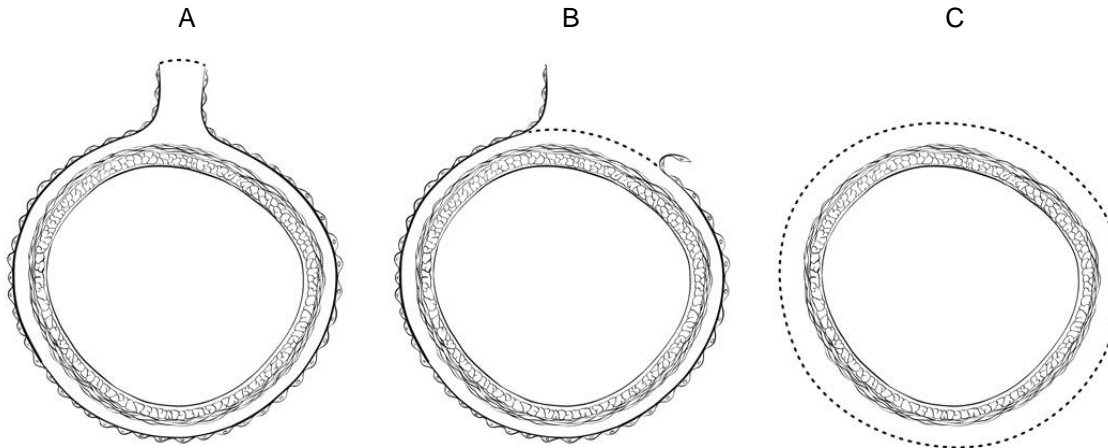
Tumor-infiltrating lymphocytes are closely associated with microsatellite instability and medullary architecture (see above) and should be distinguished from Crohn-like peritumoral infiltrates (lymphoid aggregates or follicles are the tumor edge, not associated with preexisting lymph node).<sup>33</sup> Although absolute cut-off values have not been established, only moderate- and high-density intratumoral lymphocytes (approximately 3 or more per high-power field using H&E-stained sections) should be considered significant.<sup>34</sup>

Other pathologic features associated with MSI-H status in colorectal carcinomas include right-sided location, intratumoral heterogeneity (mixed conventional, mucinous, and poorly differentiated carcinoma), high-grade histology, and lack of dirty necrosis.<sup>34</sup>

## J. Margins

It may be helpful to mark the margin(s) closest to the tumor with ink following close examination of the serosal surface for puckering and other signs of tumor involvement. Margins marked by ink should be designated in the macroscopic description of the surgical pathology report. The serosal surface (visceral peritoneum) does not constitute a surgical margin.

In addition to addressing the proximal and distal margins, the circumferential (radial) margin (Figure 3A-3C) must be assessed for any segment either unencased (Figure 3C) or incompletely encased by peritoneum (Figure 3B) (see Note A). The circumferential (radial) margin represents the adventitial soft tissue margin closest to the deepest penetration of tumor and is created surgically by blunt or sharp dissection of the retroperitoneal or subperitoneal aspect, respectively. Multivariate analysis has suggested that tumor involvement of the circumferential (radial) margin is the most critical factor in predicting local recurrence in rectal cancer.<sup>35</sup> A positive circumferential (radial) margin in rectal cancer increases the risk of recurrence by 3.5-fold and doubles the risk of death from disease. For this reason, the circumferential (radial) margin should be assessed in all rectal carcinomas as well as colonic segments with nonperitonealized surfaces. The distance between the tumor and circumferential (radial) margin should be reported (see Note H). The circumferential (radial) margin is considered negative if the tumor is more than 1 mm from the inked nonperitonealized surface but should be recorded as positive if tumor is located 1 mm or less from the nonperitonealized surface, because local recurrence rates are similar with clearances of 0 to 1 mm. This assessment includes tumor within a lymph node as well as direct tumor extension, but if circumferential resection margin positivity is based solely on intranodal tumor, this should be so stated. Although current recommendations state that intranodal or intravascular tumor within 1 mm of circumferential resection margin should be considered as a positive margin, data from a small number of patients suggest that local recurrence in these tumors may be similar to those with negative margin.<sup>35,36</sup>



**Figure 3.** A, Mesenteric margin in portion of colon completely encased by peritoneum (dotted line). B, Circumferential margin (dotted line) in portion of colon incompletely encased by peritoneum. C, Circumferential margin (dotted line) in rectum, completely unencased by peritoneum.

The mesenteric resection margin is the only relevant circumferential margin in segments completely encased by peritoneum (eg, transverse colon). Involvement of this margin should be reported even if tumor does not penetrate the serosal surface.

Sections to evaluate the proximal and distal resection margins can be obtained either by longitudinal sections perpendicular to the margin or by en face sections parallel to the margin. The distance from the tumor edge to the closest resection margin(s) may also be important, particularly for low anterior resections. For these cases, a distal resection margin of 2 cm is considered adequate; for T1 and T2 tumors, 1 cm may be sufficient distal clearance. Anastomotic recurrences are rare when the distance to the closest transverse margin is 5 cm or greater.

In cases of carcinoma arising in a background of inflammatory bowel disease, proximal and distal resection margins should be evaluated for dysplasia and active inflammation. Proximal, distal, and radial/mesenteric resection margins should be reported in all resections specimens. Deep margin and mucosal margins should be reported in all transanal disk excisions.

#### K. Treatment Effect

Neoadjuvant chemoradiation therapy in rectal cancer is associated with significant tumor response and downstaging.<sup>37</sup> Because eradication of the tumor, as detected by pathologic examination of the resected specimen, is associated with a significantly better prognosis,<sup>38</sup> specimens from patients receiving neoadjuvant chemoradiation should be thoroughly sectioned, with careful examination of the tumor site. Minimal residual disease has been shown to have a better prognosis than gross residual disease.<sup>38</sup> Several systems for tumor response have been advocated, and a modified Ryan scheme is suggested, which has been shown to provide good interobserver reproducibility provide prognostic significance.<sup>39</sup>

#### Modified Ryan Scheme for Tumor Regression Score<sup>39</sup>

Description	Tumor Regression Score
No viable cancer cells (complete response)	0
Single cells or rare small groups of cancer cells (near complete response)	1
Residual cancer with evident tumor regression, but more than single cells or rare small groups of cancer cells (partial response)	2
Extensive residual cancer with no evident tumor regression (poor or no response)	3

Tumor regression should be assessed only in the primary tumor; lymph node metastases should not be included in the assessment.

Acellular pools of mucin in specimens from patients receiving neoadjuvant therapy are considered to represent completely eradicated tumor and are not used to assign pT stage or counted as positive lymph nodes.

#### L. Tumor Deposits

Discrete tumor deposits in pericolic or perirectal fat away from the leading edge of the tumor and showing no evidence of residual lymph node tissue, but within the lymphatic drainage of the primary carcinoma, are considered tumor deposits or satellite nodules<sup>1</sup> and are not counted as lymph nodes replaced by tumor. Most examples are due to venous invasion and, less commonly, small vessel or perineural invasion. Tumor deposits are associated with reduced disease-free and overall survival,<sup>40,41</sup> and their number should be recorded in the surgical pathology report. If 1 or more tumor deposits are observed in the absence of identifiable lymph node metastasis, it should be categorized as N1c. This rule applies irrespective of T category. If tumor deposits are accompanied by identifiable lymph node metastasis, it does not affect the N category, which is then determined by the number of positive lymph nodes (see note M).

#### M. TNM and Anatomic Stage/Prognostic Groupings

Surgical resection remains the most effective therapy for colorectal carcinoma, and the best estimation of prognosis is derived from the pathologic findings on the resection specimen. The anatomic extent of disease is by far the most important prognostic factor in colorectal cancer.

The protocol recommends the TNM staging system of the American Joint Committee on Cancer (AJCC) and the International Union Against Cancer (UICC)<sup>1</sup> but does not preclude the use of other staging systems.

By AJCC/UICC convention, the designation “T” refers to a primary tumor that has not been previously treated. The symbol “p” refers to the pathologic classification of the TNM, as opposed to the clinical classification, and is based on gross and microscopic examination. pT entails a resection of the primary tumor or biopsy adequate to evaluate the highest pT category, pN entails removal or biopsy of nodes adequate to validate lymph node metastasis, and pM implies microscopic examination of distant lesions. Clinical classification (cTNM) is usually carried out by the referring physician before treatment during initial evaluation of the patient or when pathologic classification is not possible.

#### TNM Descriptors

For identification of special cases of TNM or pTNM classifications, the “m” suffix and “y” and “r” prefixes are used. Although they do not affect the stage grouping, they indicate cases needing separate analysis.

The “m” suffix indicates the presence of multiple primary tumors in a single site and is recorded in parentheses: pT(m)NM.

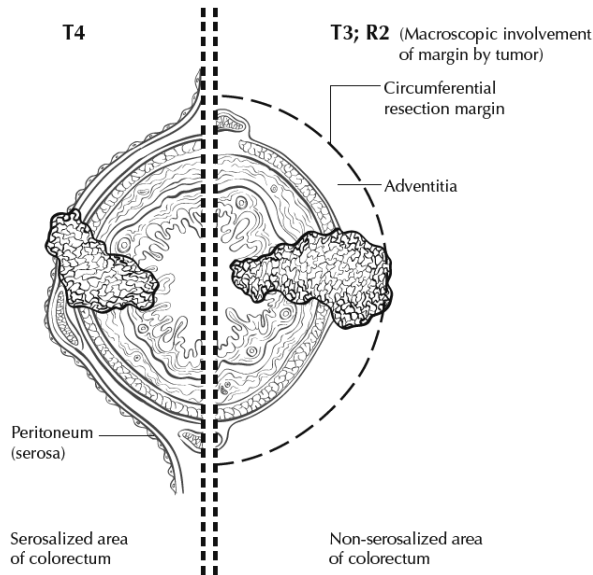
The “y” prefix indicates those cases in which classification is performed during or following initial multimodality therapy (ie, neoadjuvant chemotherapy, radiation therapy, or both chemotherapy and radiation therapy). The cTNM or pTNM category is identified by a “y” prefix. The ycTNM or ypTNM categorizes the extent of tumor actually present at the time of that examination. The “y” categorization is not an estimate of tumor prior to multimodality therapy (ie, before initiation of neoadjuvant therapy).

The “r” prefix indicates a recurrent tumor when staged after a documented disease-free interval, and is identified by the “r” prefix: rTNM.

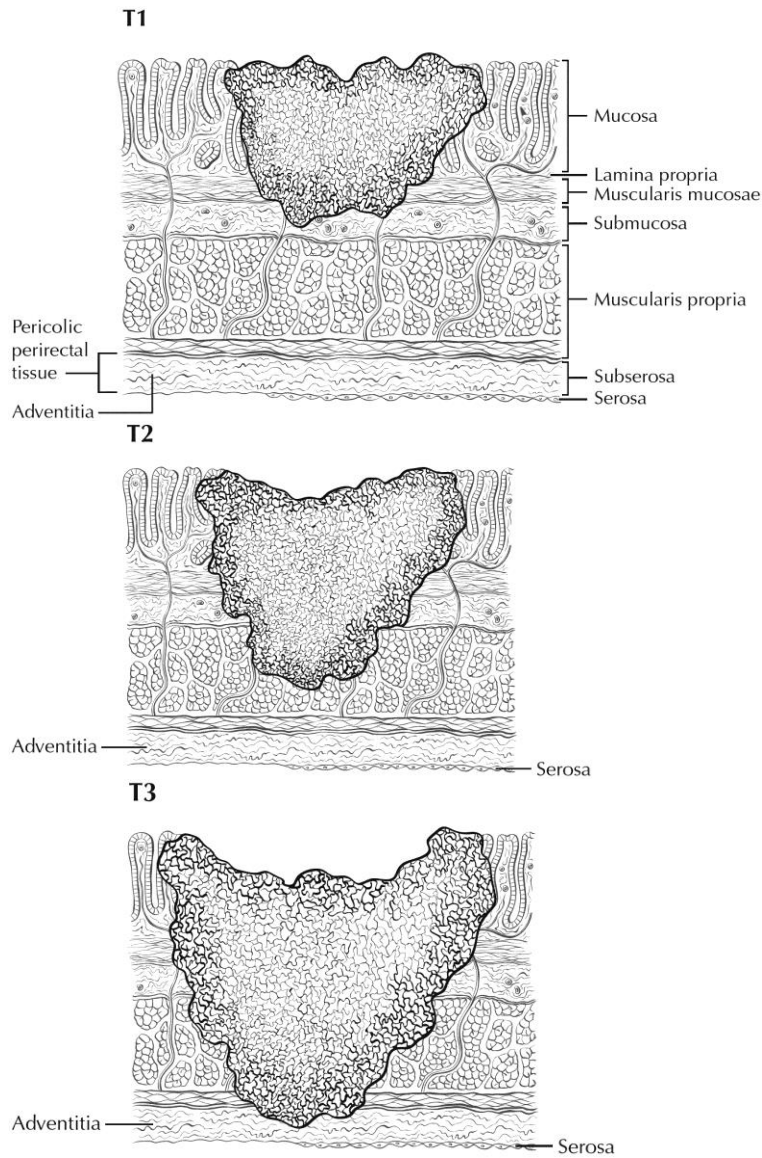
#### T Category Considerations (Figures 4-6)

pTis. For colorectal carcinomas, *carcinoma in situ* (pTis) as a staging term includes cancer cells confined within the glandular basement membrane (high-grade dysplasia) or involving the lamina propria and/or muscularis mucosae, but not extending through it (intramucosal carcinoma). Tumor extension through the muscularis mucosae into the submucosa is classified as T1 (Figure 5).

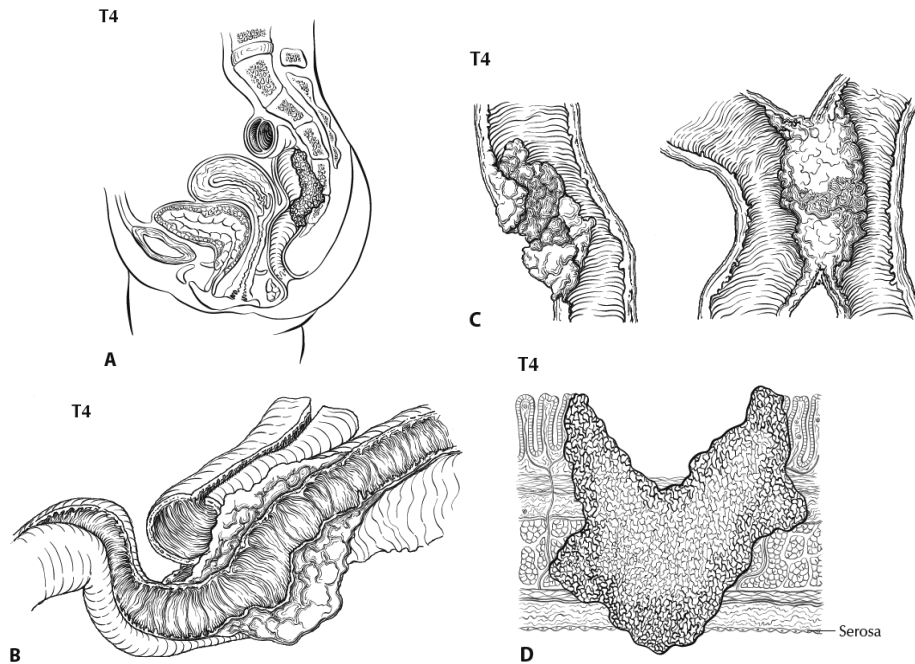
**pT4.** Tumors that involve the serosal surface (visceral peritoneum) or directly invade adjacent organs or structures are assigned to the T4 category (Figures 4 and 6).



**Figure 4.** T4 (left side) with involvement of serosa (visceral peritoneum) by tumor cells in a segment of colorectum with a serosal covering. In contrast, the right side of the diagram shows T3 with macroscopically positive circumferential margin (designated R2 in AJCC staging system), corresponding to gross disease remaining after surgical excision. Used with permission of the American Joint Committee on Cancer (AJCC), Chicago, Ill. The original source for this material is the *AJCC Cancer Staging Atlas* (2006) edited by Greene et al<sup>2</sup> and published by Springer Science and Business Media, LLC, [www.springerlink.com](http://www.springerlink.com).



**Figure 5.** T1 tumor invades submucosa; T2 tumor invades muscularis propria; T3 tumor invades through the muscularis propria into the subserosa or into nonperitonealized pericolonic or perirectal tissues (adventitia). Used with permission of the American Joint Committee on Cancer (AJCC), Chicago, Ill. The original source for this material is the *AJCC Cancer Staging Atlas* (2006) edited by Greene et al<sup>2</sup> and published by Springer Science and Business Media, LLC, [www.springerlink.com](http://www.springerlink.com).



**Figure 6.** A, T4b tumor showing direct invasion of coccyx. B, T4 tumor directly invading adjacent loop of small bowel. C, T4 tumor showing gross perforation of bowel through tumor (left). The right-hand panel shows T4 tumor directly invading adjacent bowel. D, T4a tumor with involvement of serosa (visceral peritoneum) by tumor cells. Used with permission of the American Joint Committee on Cancer (AJCC), Chicago, Ill. The original source for this material is the *AJCC Cancer Staging Atlas* (2006) edited by Greene et al<sup>2</sup> and published by Springer Science and Business Media, LLC, www.springerlink.com.

Tumor that is adherent to other organs or structures macroscopically is classified as T4. However, if no tumor is found within the adhesion microscopically, the tumor should be assigned T3.<sup>1</sup>

For rectal tumors, invasion of the external sphincter is classified as T3, whereas invasion of the levator ani muscle(s) is classified as T4.

Tumor in veins or lymphatics does not affect the pT classification.

Subdivision of T4 into T4a and T4b. Serosal (visceral peritoneal) involvement by tumor cells (pT4a) has been demonstrated by multivariate analysis to have a negative impact on prognosis,<sup>42,43</sup> as does direct invasion of adjacent organs (pT4b). Visceral peritoneal involvement can be missed without thorough sampling and/or sectioning, and malignant cells have been identified in serosal scrapings in as many as 26% of specimens categorized as pT3 by histologic examination alone.<sup>43,44</sup> Although the absence of standard guidelines for assessing peritoneal involvement may contribute to underdiagnosis, the following findings are considered to represent serosal involvement by tumor:

- Tumor present at the serosal surface
- Free tumor cells on the serosal surface (on the visceral peritoneum) with underlying erosion/ulceration of mesothelial lining, mesothelial hyperplasia and/or inflammatory reaction<sup>42,43</sup>
- Perforation in which the tumor cells are continuous with the serosal surface through inflammation

The significance of tumors that are <1 mm from the serosal surface and accompanied by serosal reaction is unclear, with some<sup>43</sup> but not all studies<sup>42</sup> indicating a higher risk of peritoneal recurrence. Multiple level sections and/or additional section of the tumor should be examined in these cases. If the serosal involvement is not present after additional evaluation, the tumor should be assigned to the pT3 category. In portions of the colorectum that are not peritonealized (eg, posterior aspects of ascending and descending colon, lower portion of rectum), the T4a category is not applicable.

Intramural extension of tumor from 1 subsite (segment) of the large intestine into an adjacent subsite or into the ileum (eg, for a cecal carcinoma) or anal canal (eg, for a rectal carcinoma) does not affect the pT classification. Transmural extension into another organ or site is necessary for T4b designation.

Both types of peritoneal involvement are associated with decreased survival. Although small studies suggested that serosal involvement was associated with worse outcome than invasion of adjacent organs, data from a large cohort of more than 100,000 colon cancer cases<sup>45</sup> indicate that penetration of the visceral peritoneum carries a 10% to 20% better 5-year survival than locally invasive carcinomas for each category of N. Therefore, designation of the T4 subsets was changed in the seventh edition of the *AJCC Cancer Staging Manual* to reflect these new findings.

### N Category Considerations

The regional lymph nodes for the anatomical subsites of the large intestine (Figure 7) are as follows:

Cecum: anterior cecal, posterior cecal, ileocolic, right colic

Ascending colon: ileocolic, right colic, middle colic

Hepatic flexure: middle colic, right colic

Transverse colon: middle colic

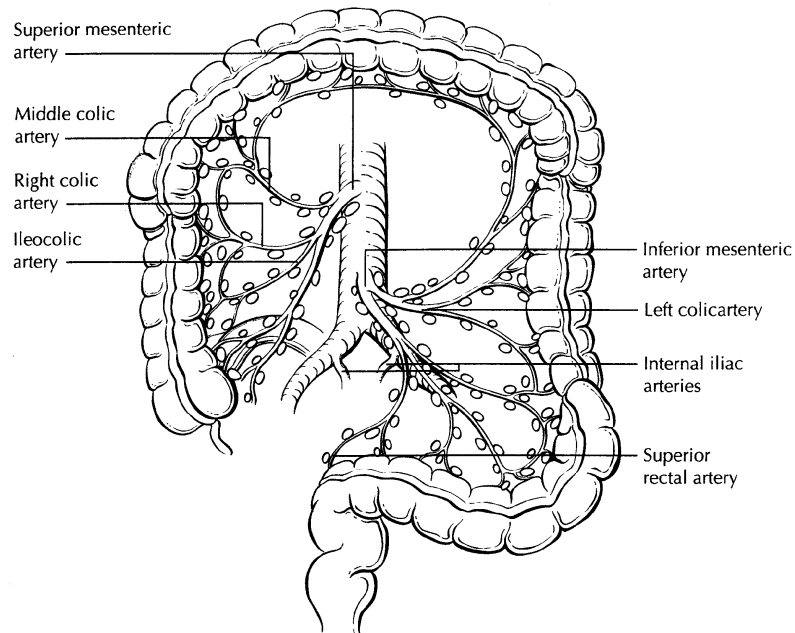
Splenic flexure: middle colic, left colic, inferior mesenteric

Descending colon: left colic, inferior mesenteric, sigmoid

Sigmoid colon: inferior mesenteric, superior rectal sigmoidal, sigmoid mesenteric

Rectosigmoid: perirectal, left colic, sigmoid mesenteric, sigmoidal, inferior mesenteric, superior rectal, middle rectal

Rectum: perirectal, sigmoid mesenteric, inferior mesenteric, lateral sacral, presacral, internal iliac, sacral promontory, superior rectal, middle rectal, inferior rectal



**Figure 7.** The regional lymph nodes of the colon and rectum. Used with permission of the American Joint Committee on Cancer (AJCC), Chicago, Ill. The original source for this material is the *AJCC Cancer Staging Atlas* (2006) edited by Greene et al<sup>2</sup> and published by Springer Science and Business Media, LLC, [www.springerlink.com](http://www.springerlink.com).

Nodes along the sigmoid arteries are considered pericolic nodes, and their involvement is classified as N1 or N2 according to the number involved.



Perirectal lymph nodes include the mesorectal (paraproctal), lateral sacral, presacral, sacral promontory (Gerota), middle rectal (hemorrhoidal), and inferior rectal (hemorrhoidal) nodes. Metastasis in the external iliac or common iliac nodes is classified as distant metastasis.<sup>1</sup>

Submission of Lymph Nodes for Microscopic Examination. All grossly negative or equivocal lymph nodes are to be submitted entirely.<sup>13</sup> Grossly positive lymph nodes may be partially submitted for microscopic confirmation of metastasis.

The accuracy and predictive value of stage II assignment are directly proportional to the thoroughness of the surgical technique in removing all regional nodes and the pathologic examination of the resection specimen in identifying and harvesting all regional lymph nodes for microscopic assessment. It has been suggested that 12 lymph nodes be considered the minimal acceptable harvest from a careful specimen dissection.<sup>13</sup> In 2007, the National Quality Forum listed the presence of at least 12 lymph nodes in a surgical resection among the key quality measures for colon cancer care in the United States (see <http://www.facs.org/cancer/qualitymeasures.html>).

Increasingly, however, evidence indicates that this bar should be raised, as the greater the number of nodes examined, the greater the likelihood that metastasis will be found, suggesting that no minimum number of nodes accurately or reliably stages all patients.<sup>45,46</sup>

More importantly, it has been shown that clinical outcome is linked to lymph node harvest in stage II disease. Numerous studies have shown that conventional pathologic examination of increased numbers of lymph nodes is itself associated with an increased survival advantage in stage II disease,<sup>47</sup> indicating a positive effect of optimal mesenteric resection by the surgeon, optimal lymph node harvest from the resection specimen by the pathologist, or both.

The number of lymph nodes recovered from a resection specimen is dependent on several factors. Surgical technique, surgery volume, and patient factors (eg, age and anatomic variation) alter the actual number of nodes in a resection specimen, but the diligence and skill of the pathologist in identifying and harvesting lymph nodes in the resection specimen also are major factors. Lymph nodes may be more difficult to identify in specimens from patients who are obese<sup>48</sup> or elderly, or after neoadjuvant therapy.<sup>49</sup> Because it has been shown that nodal metastasis in colorectal cancer is often found in small lymph nodes (<5 mm in diameter), diligent search for lymph nodes is required on gross examination of resection specimens. If fewer than 12 lymph nodes are found, re-examining the specimen for additional lymph nodes, with or without visual enhancement techniques, should be considered.<sup>13</sup> The pathology report should clearly state the total number of lymph nodes examined and the total number involved by metastases. Data are insufficient to recommend routine use of tissue levels or special/ancillary techniques.

Nonregional Lymph Nodes. For microscopic examination of lymph nodes in large resection specimens, lymph nodes must be designated as regional versus nonregional, according to the anatomic location of the tumor. Metastasis to nonregional lymph nodes is classified as distant metastasis and designated as M1.

Lymph Nodes Replaced by Tumor. A tumor nodule in the pericolonic/perirectal fat without histologic evidence of residual lymph node tissue is classified as a tumor deposit (peritumoral deposit or satellite nodule) and is not considered a positive lymph node. Such tumor deposits may represent discontinuous spread, lymph-vascular spread with extravascular extension, or totally replaced lymph nodes. In the absence of unequivocal lymph node metastases, tumor deposits are recorded as N1c.<sup>1</sup>

Micrometastasis and Isolated Tumor Cells. A micrometastasis is defined as tumor measuring greater than 0.2 mm but less than or equal to 2.0 mm in greatest dimension. Micrometastases are classified as N1(mic) or M1(mic) in lymph nodes or at distant sites, respectively. Isolated tumor cells (ITCs) are defined as single tumor cells or small clusters of tumor cells measuring 0.2 mm or less, usually found by special techniques such as immunohistochemical staining, and are classified as N0.<sup>4</sup> Because the biologic significance of ITCs (either a single focus in a single node, multiple foci within a single node, or micrometastatic involvement of multiple nodes) remains unproven, N0 is considered justified. The number of lymph nodes involved by micrometastases or ITCs should be clearly stated in a comment section or elsewhere in the report.

Routine assessment of regional lymph nodes is limited to conventional pathologic techniques (gross assessment and histologic examination), and data are currently insufficient to recommend special measures to detect micrometastasis or ITCs. Thus, neither multiple levels of paraffin blocks nor the use of special/ancillary techniques such as immunohistochemistry are recommended for routine examination of regional lymph nodes.

### TNM Anatomic Stage/Prognostic Groupings

Pathologic staging is usually performed after surgical resection of the primary tumor. Pathologic staging depends on pathologic documentation of the anatomic extent of disease, whether or not the primary tumor has been completely removed. If a biopsied tumor is not resected for any reason (eg, when technically unfeasible), and if the highest T and N categories or the M1 category of the tumor can be confirmed microscopically, the criteria for pathologic classification and staging have been satisfied without total removal of the primary cancer.

#### TNM Stage Groupings

Stage 0	Tis	N0	M0 <sup>#</sup>
Stage I	T1	N0	M0
	T2	N0	M0
Stage IIA	T3	N0	M0
Stage IIB	T4a	N0	M0
Stage IIC	T4b	N0	M0
Stage IIIA	T1-T2	N1	M0
	T1	N2a	M0
Stage IIIB	T3-T4a	N1	M0
	T2-T3	N2a	M0
	T1-T2	N2b	M0
Stage IIIC	T4a	N2a	M0
	T3-T4a	N2b	M0
	T4b	N1-N2	M0
Stage IVA	Any T	Any N	M1a
Stage IVB	Any T	Any N	M1b

<sup>#</sup> M0 is defined as no distant metastasis.<sup>1</sup>

### References

1. Edge SB, Byrd DR, Carducci MA, Compton CC, eds. *AJCC Cancer Staging Manual*. 7th ed. New York, NY: Springer; 2009.
2. Greene FL, Compton CC, Fritz AG, Shah J, Winchester DP, eds. *AJCC Cancer Staging Atlas*. New York, NY: Springer; 2006.
3. Fielding LP, Arsenault PA, Chapuis PH, et al. Clinicopathological staging for colorectal cancer: an International Documentation System (IDS) and an International Comprehensive Anatomical Terminology (ICAT). *J Gastroenterol Hepatol*. 1991;6(4):325-344.
4. Wittekind C, Henson DE, Hutter RVP, Sobin LH, eds. *TNM Supplement: A Commentary on Uniform Use*. 2nd ed. New York, NY: Wiley-Liss; 2001.
5. Kenig J, Richter P. Definition of the rectum and level of the peritoneal reflection - still a matter of debate? *Wideochir Inne Tech Malo Inwazyjne*. 2013;8:183-186.
6. Bosman FT, Carneiro F, Hruban RH, Theise ND, eds. *WHO Classification of Tumours of the Digestive System*. Geneva, Switzerland: WHO Press; 2010.
7. Kang H, O'Connell JB, Maggard MA, Sack J, Ko CY. A 10-year outcomes evaluation of mucinous and signet-ring cell carcinoma of the colon and rectum. *Dis Colon Rectum*. 2005;48(6):1161-1168.
8. Bernick PE, Klimstra DS, Shia J, et al. Neuroendocrine carcinomas of the colon and rectum. *Dis Colon Rectum*. 2004;47(2):163-169.
9. Wick MR, Vitsky JL, Ritter JH, Swanson PE, Mills SE. Sporadic medullary carcinoma of the colon: a clinicopathologic comparison with nonhereditary poorly differentiated enteric-type adenocarcinoma and neuroendocrine colorectal carcinoma. *Am J Clin Pathol*. 2005;123:56-65.
10. Jass JR. Pathology of hereditary nonpolyposis colorectal cancer. *Ann N Y Acad Sci*. 2000;910:62-73; discussion 73-64.

11. Jass JR, Atkin WS, Cuzick J, et al. The grading of rectal cancer: historical perspectives and a multivariate analysis of 447 cases. *Histopathology*. 1986;10(5):437-459.
12. Compton CC. Colorectal cancer. In: Gospodarowicz MK, O'Sullivan B, Sobin LH, eds. *Prognostic Factors in Cancer*. New York, NY: Wiley-Liss; 2006:133-137.
13. Compton CC, Fielding LP, Burgart LJ, et al. Prognostic factors in colorectal cancer. College of American Pathologists Consensus Statement 1999. *Arch Pathol Lab Med*. 2000;124(7):979-994.
14. Cooper HS. Pathology of endoscopically removed malignant colorectal polyp. *Curr Diagn Pathol*. 2007;13(6):423-437.
15. Cooper HS, Deppisch LM, Gourley WK, et al. Endoscopically removed malignant colorectal polyps: clinical pathological correlations. *Gastroenterology*. 1995;108(6):1657-1665.
16. Coverlizza S, Risio M, Ferrari A, Fenoglio-Preiser CM, Rossini FP. Colorectal adenomas containing invasive carcinoma: pathologic assessment of lymph node metastatic potential. *Cancer*. 1989;64(9):1937-1947.
17. Lim SB, Yu CS, Jang SJ, Kim TW, Kim JH, Kim JC. Prognostic significance of lymphovascular invasion in sporadic colorectal cancer. *Dis Colon Rectum*. 2010;53(4):377-384.
18. Santos C, López-Doriga A, Navarro M, et al. Clinicopathological risk factors of Stage II colon cancer: results of a prospective study. *Colorectal Dis*. 2013;15(4):414-422.
19. Betge J, Pollheimer MJ, Lindtner RA, et al. Intramural and extramural vascular invasion in colorectal cancer: prognostic significance and quality of pathology reporting. *Cancer*. 2012;118(3):628-638.
20. Messenger DE, Driman DK, Kirsch R. Developments in the assessment of venous invasion in colorectal cancer: implications for future practice and patient outcome. *Hum Pathol*. 2012;43(7):965-973.
21. Kirsch R, Messenger DE, Riddell RH, et al. Venous invasion in colorectal cancer: impact of an elastin stain on detection and interobserver agreement among gastrointestinal and nongastrointestinal pathologists. *Am J Surg Pathol*. 2013;37(2):200-210.
22. Liebig C, Ayala G, Wilks J, et al. Perineural invasion is an independent predictor of outcome in colorectal cancer. *J Clin Oncol*. 2009;27(31):5131-5137.
23. Ueno H, Shirouzu K, Eishi Y, et al; Study Group for Perineural Invasion projected by the Japanese Society for Cancer of the Colon and Rectum (JSCCR). Characterization of perineural invasion as a component of colorectal cancer staging. *Am J Surg Pathol*. 2013;37(10):1542-1549.
24. Gomez D, Zaitoun AM, De Rosa A, et al. Critical review of the prognostic significance of pathological variables in patients undergoing resection for colorectal liver metastases. *HPB (Oxford)*. 2014;16(9):836-844.
25. Peng SL, Thomas M, Ruszkiewicz A, Hunter A, Lawrence M, Moore J. Conventional adverse features do not predict response to adjuvant chemotherapy in stage II colon cancer. *ANZ J Surg*. 2014;84(11):837-841.
26. Ozturk MA, Dane F, Karagoz S, et al. Is perineural invasion (PN) a determinant of disease free survival in early stage colorectal cancer? *Hepatogastroenterology*. 2015;62(137):59-64.
27. Huh JW, Kim HR, Kim YJ. Prognostic value of perineural invasion in patients with stage II colorectal cancer. *Ann Surg Oncol*. 2010;17(8):2066-2072.
28. Snover DC, Jass JR, Fenoglio-Preiser C, Batts KP. Serrated polyps of the large intestine: a morphologic and molecular review of an evolving concept.[see comment]. *Am J Clin Pathol*. 2005;124(3):380-391.
29. Anwar MA, D'Souza F, Coulter R, Memon B, Khan IM, Memon MA. Outcome of acutely perforated colorectal cancers: experience of a single district general hospital. *Surg Oncol*. 2006;15(2):91-96.
30. Arbman G, Nilsson E, Hallbook O, Sjodahl R. Local recurrence following total mesorectal excision for rectal cancer. *Br J Surg*. 1996;83(3):375-379.
31. Kapiteijn E, Marijnen CA, Nagtegaal ID, et al. Preoperative radiotherapy combined with total mesorectal excision for resectable rectal cancer. *N Engl J Med*. 2001;345(9):638-646. [summary for patients in Med J Aust. 2002 Nov 18;177(10):563-564; PMID: 12429007]
32. Umar A, Boland CR, Terdiman JP, et al. Revised Bethesda guidelines for hereditary nonpolyposis colorectal cancer (Lynch syndrome) and microsatellite instability. *J Natl Cancer Inst*. 2004;96(4):261-268.
33. Alexander J, Watanabe T, Wu T-T, Rashid A, Li S, Hamilton SR. Histopathological identification of colon cancer with microsatellite instability. *Am J Pathol*. 2001;158(2):527-535.
34. Greenson JK, Bonner JD, Ben-Yzhak O, et al. Phenotype of microsatellite unstable colorectal carcinomas. *Am J Surg Pathol*. 2003;27(5):563-570.
35. Birbeck KF, Macklin CP, Tiffin NJ, et al. Rates of circumferential resection margin involvement vary between surgeons and predict outcomes in rectal cancer surgery. *Ann Surg*. 2002;235(4):449-457.
36. Nagtegaal ID, Marijnen CA, Kranenbarg EK, van de Velde CJ, van Krieken JH; Pathology Review Committee; Cooperative Clinical Investigators. Circumferential margin involvement is still an important

- predictor of local recurrence in rectal carcinoma: not one millimeter but two millimeters is the limit. *Am J Surg Pathol.* 2002;26(3):350-357.
37. Ruo L, Tickoo S, Klimstra DS, et al. Long-term prognostic significance of extent of rectal cancer response to preoperative radiation and chemotherapy. *Ann Surg.* 2002;236(1):75-81.
  38. Gavioli M, Luppi G, Losi L, et al. Incidence and clinical impact of sterilized disease and minimal residual disease after preoperative radiochemotherapy for rectal cancer. *Dis Colon Rectum.* 2005;48(10):1851-1857.
  39. Ryan R, Gibbons D, Hyland JMP, et al. Pathological response following long-course neoadjuvant chemoradiotherapy for locally advanced rectal cancer. *Histopathology.* 2005;47(2):141-146.
  40. Lo DS, Pollett A, Siu LL, et al. Prognostic significance of mesenteric tumor nodules in patients with stage III colorectal cancer. *Cancer.* 2008;112(1):50-54.
  41. Puppa G, Maisonneuve P, Sonzogni A, et al. Pathological assessment of pericolic tumor deposits in advanced colonic carcinoma: relevance to prognosis and tumor staging. *Mod Pathol.* 2007;20(8):843-855.
  42. Shepherd NA, Baxter KJ, Love SB. The prognostic importance of peritoneal involvement in colonic cancer: a prospective evaluation. *Gastroenterology.* 1997;112(4):1096-1102.
  43. Panarelli NC, Schreiner AM, Brandt SM, Shepherd NA, Yantiss RK. Histologic features and cytologic techniques that aid pathologic stage assessment of colonic adenocarcinoma. *Am J Surg Pathol.* 2013;37(8):1252-1258.
  44. Gunderson LL, Jessup JM, Sargent DJ, Greene FL, Stewart A. TN categorization for rectal and colon cancers based on national survival outcome data. *J Clin Oncol.* 2008;26(15S):4020.
  45. Cserni G, Vinh-Hung V, Burzykowski T. Is there a minimum number of lymph nodes that should be histologically assessed for a reliable nodal staging of T3N0M0 colorectal carcinomas? *J Surg Oncol.* 2002;81(2):63-69.
  46. Goldstein NS. Lymph node recoveries from 2427 pT3 colorectal resection specimens spanning 45 years. *Am J Surg Pathol.* 2002;26(2):179-189.
  47. Chang GJ, Rodriguez-Bigas MA, Skibber JM, Moyer VA. Lymph node evaluation and survival after curative resection of colon cancer: systematic review. [Review]. *J Natl Cancer Inst.* 2007;99(6):433-441.
  48. Gorog D, Nagy P, Peter A, Perner F. Influence of obesity on lymph node recovery from rectal resection specimens. *Pathol Oncol Res.* 2003;9(3):180-183.
  49. Wijesuriya RE, Deen KI, Hewavisenthi J, Balawardana J, Perera M. Neoadjuvant therapy for rectal cancer down-stages the tumor but reduces lymph node harvest significantly. *Surg Today.* 2005;35(6):442-445.