

3RD Dimension of SNOMED-CT

Srdjan Prodanovich, MD, FAAD

Naples, Florida



Focus on the Patient and Family



COPYRIGHT © 2020 EZDERM, LLC – All Rights Reserved





The Doctor - Sir Samuel Luke Fildes (1887)

Cost of Technology



COPYRIGHT © 2020 EZDERM, LLC – All Rights Reserved



The Cost of Technology



© 2011 Thomas G. Murphy, MD.

JAMA, June 20, 2012—Vol 307, No. 23 2497

©2012 American Medical Association. All rights reserved.



COPYRIGHT © 2020 EZDERM, LLC – All Rights Reserved



The Cost of Technology

Visit Note (Dec 21, 2010 3 of 3) (Supervising: JS Performing: RG)

AARON, JOHN W Male 81 yr(s) 8 mo(s) 100-00-7584 No Known Allergies Balance: 0

Dec 21, 2010 (Procedure: New Patient Case: GENERAL 02) QRReminder NA

General:
 Office: SM Gastro Care
 Provider: Ronald Gastroenterologist, MD
 Encounter Date: Dec 21, 2010

Patient: Aaron, John W (9851)
 Gender: Male
 DOB: Apr 09, 1929 Age: 81 year 8 month
 Address: 3456 Maple Street, Clearwater FL 33758

Insurance: BC/BS OF KANSAS
 Primary Dr.: Christina WRIGHT

Reason for Visit: [Cnv. Trans. To Note] [Prev. Visit] [Add/Edit Note]
 The patient is a 81 year 8 month old, male, seen in outpatient consultation for abdominal cramps, abdominal pain and bloating.

HPI: [Cnv. Trans. To Note] [Prev. Visit] [Add/Edit Note]
 Patient came in complaining of abdominal pain. Symptom started 2 weeks ago, sudden, usually lasts intermittently. He rates the pain as 8/10 with zero being no pain and 10 being worst pain possible. Pain is located on the periumbilical region. Pain is described as aching, shooting, squeezing and throbbing. It radiates to the right middle back. Associated symptoms include bleeding per rectum. It gets better with antacids, bowel movement, light meals and meditation. No prior consultations were done. He denies any other illnesses. For the condition, a Barium enema was done on Nov 17, 2010. which did not reveal any significant findings.

Allergy: [Add/Edit Note]
 No Known Allergies

Assessment: [Prev. Visit] [Add/Edit Note]
 1. Abdominal lymphangiogram

Plan:

Colonoscopy Instructions
 EGD Instructions

Document
 Dashboard
 Show Link
 Go To
 Option
 Print
 Fax
 Super Bill
 Follow Up
 Letter
 Summary
 Sign Off
 Copy From
 * Template
 * Prv. Visit
 Note
 Image
 Prvt Note
 ECG | Spiro
 Reminder
 Analysis
 * Template
 * Flowsheet
 * Vital
 * Lab
 * PQRI
 CHDP

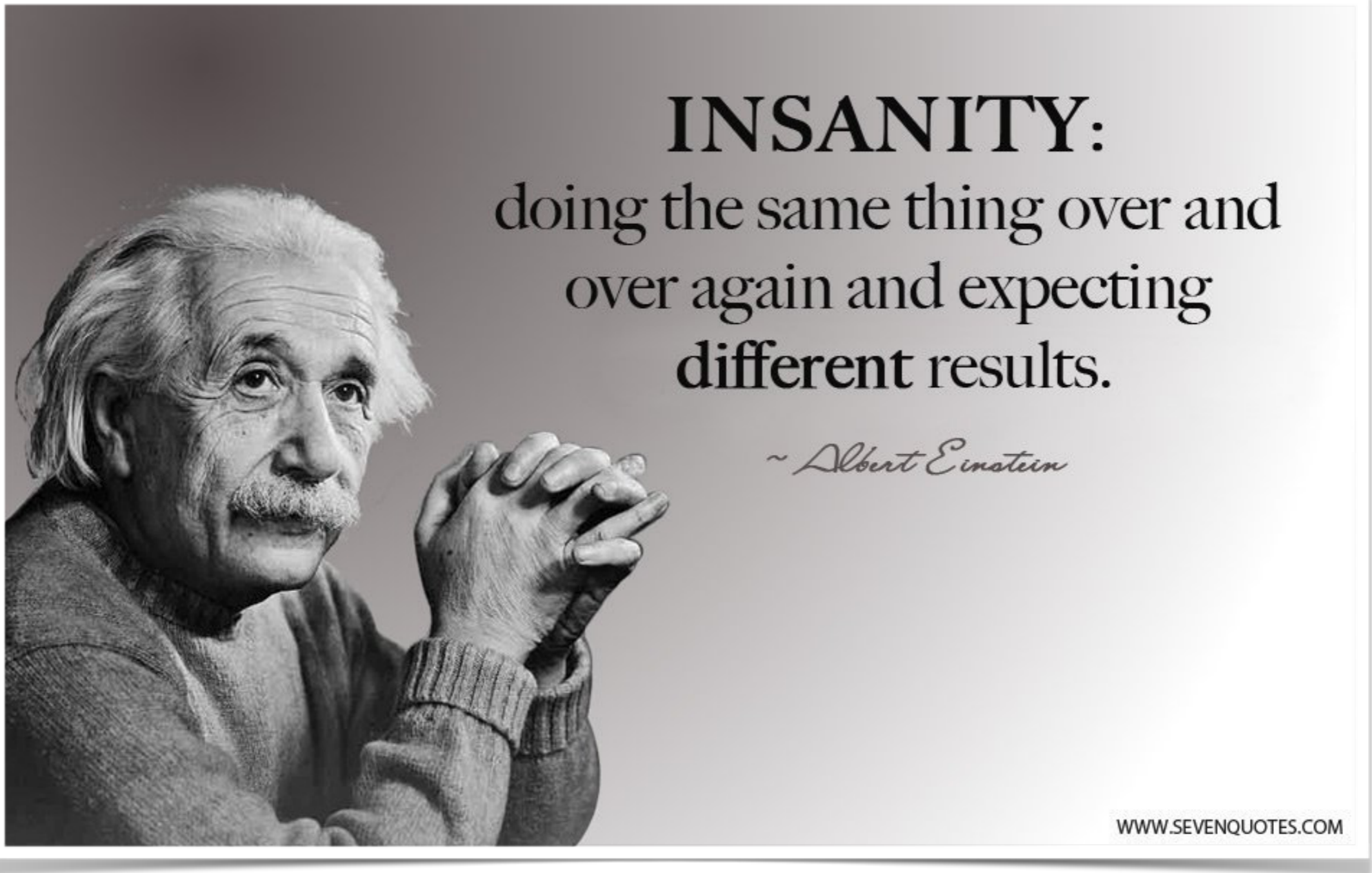
Survey of Physicians Shows Declining Satisfaction with Electronic Health Records

Compared to five years ago, more physicians are reporting being
dissatisfied
or
very dissatisfied
with their EHR system

– American Medical Association (AMA) based on a survey of physicians (2014)

https://www.acponline.org/newsroom/ehrs_satisfaction_survey.htm

<http://www.americanehr.com/research/reports/Physicians-Use-of-EHR-Systems-2014.aspx>



INSANITY:

doing the same thing over and over again and expecting different results.

~ Albert Einstein

WWW.SEVENQUOTES.COM



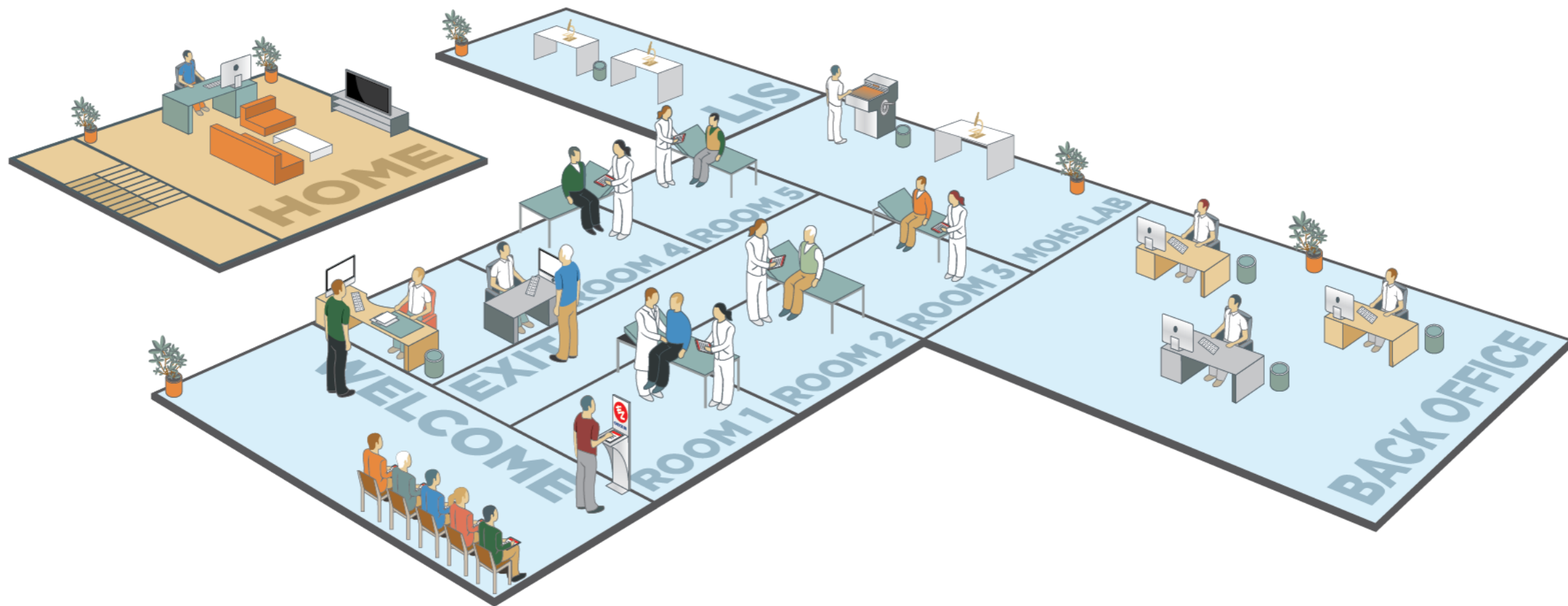
ONE

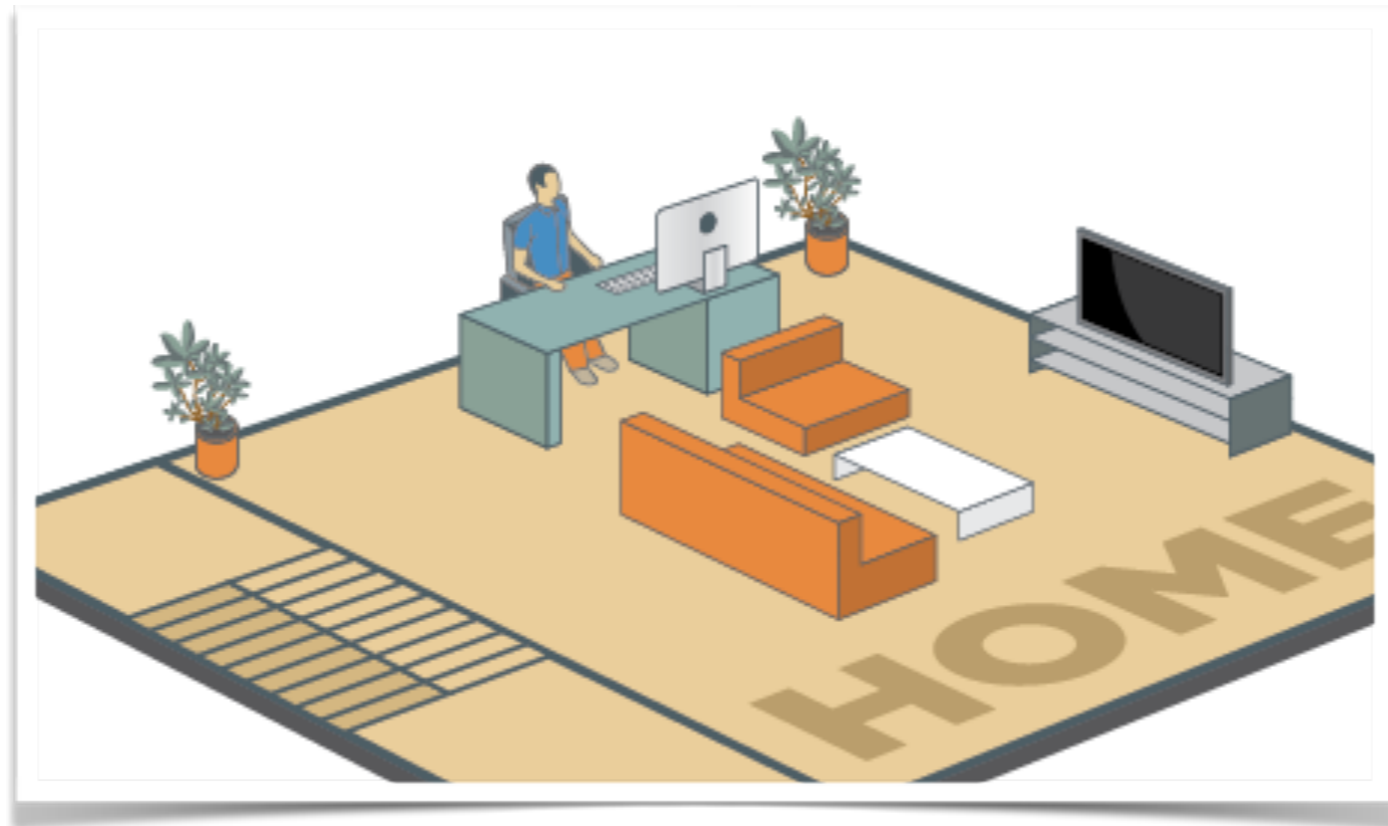
POWERFUL SYSTEM

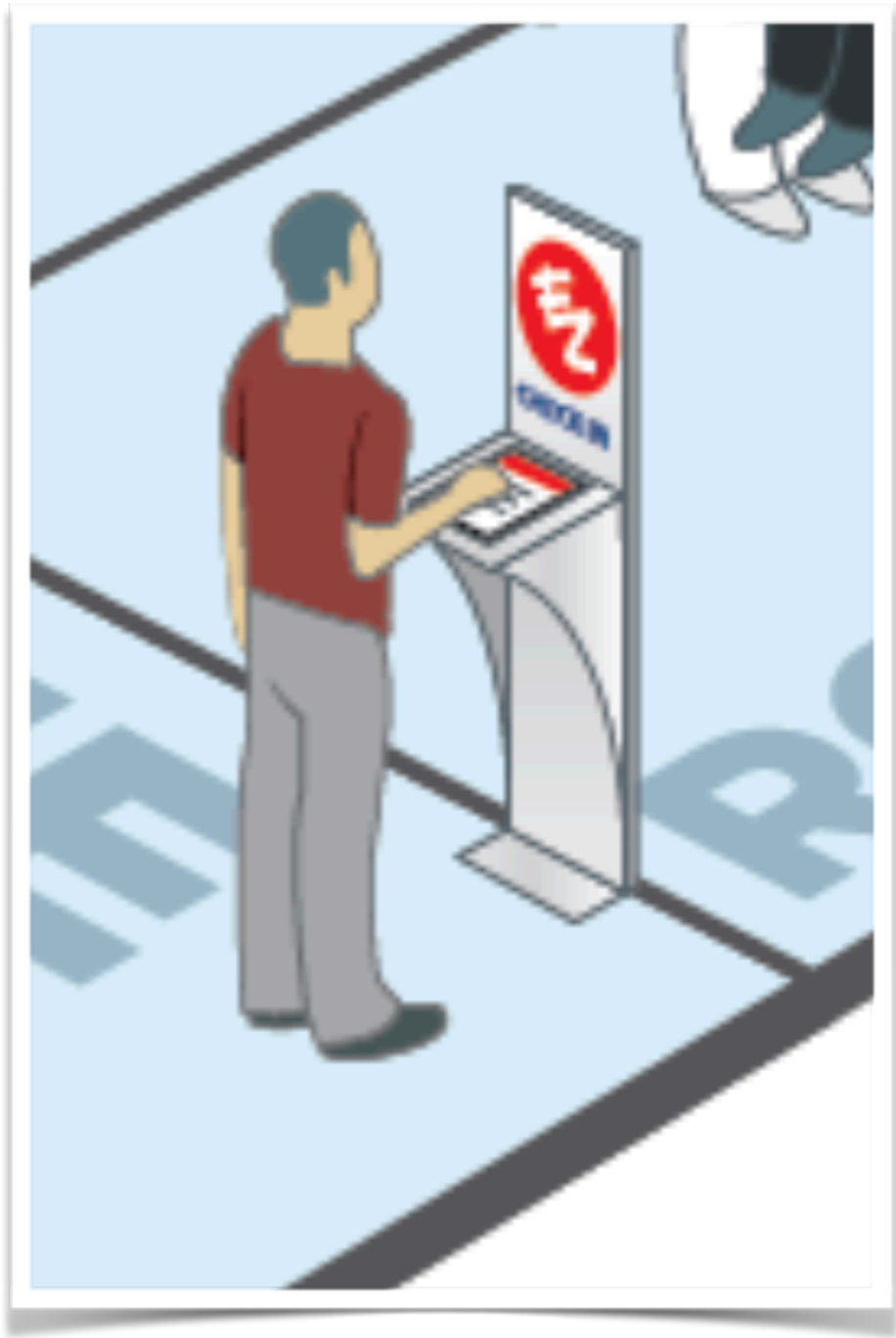

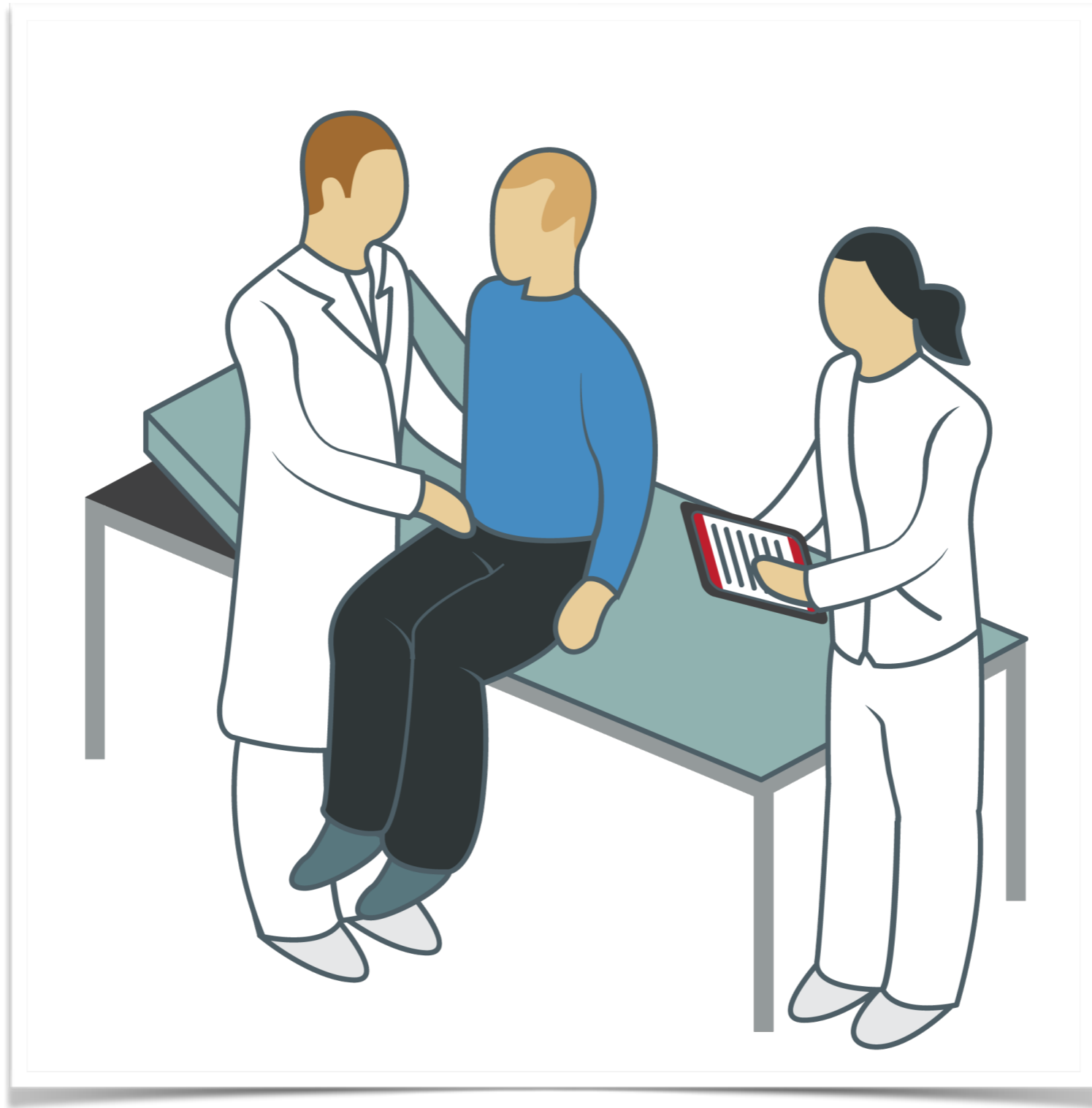
COPYRIGHT © 2020 EZDERM, LLC – All Rights Reserved








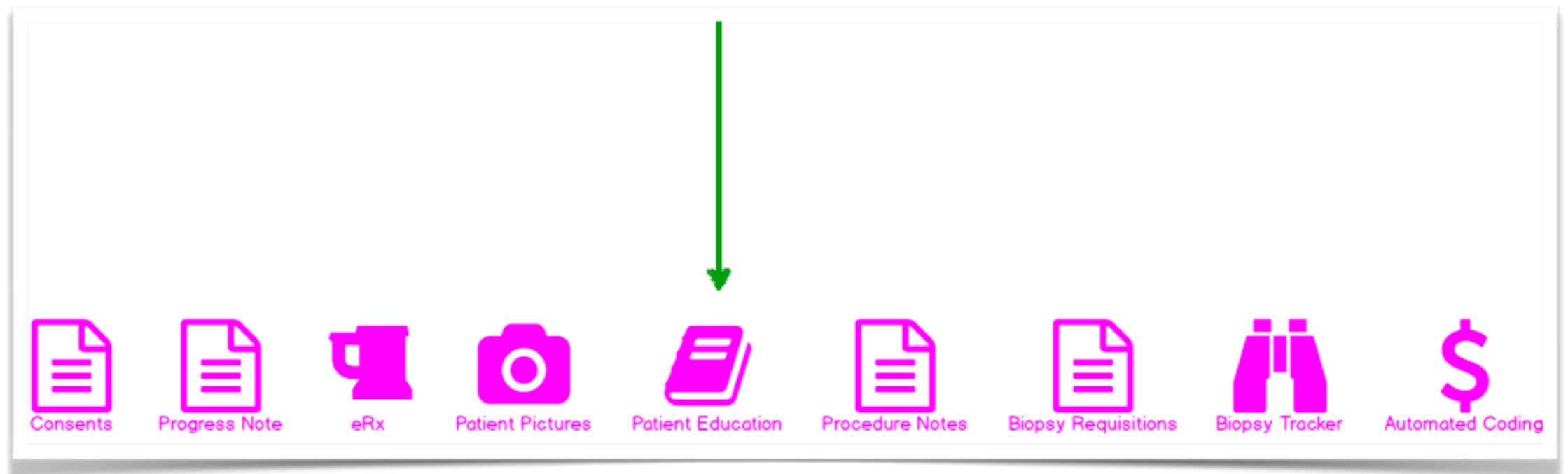




Ease of Use



Real Time Documentation



Structured Data



<http://www.lovethepic.com/image/21677/sand-castle>



COPYRIGHT © 2020 EZDERM, LLC – All Rights Reserved





SNOMED CT



Roger A. Cote, MD, FACMI



COPYRIGHT © 2020 EZDERM, LLC – All Rights Reserved



SNOMED-CT

Systemic Nomenclature Of Medicine - Clinical Terminology

Over **311,000** clinical concepts

“Physician-**friendly**”

Logic-based (clinical-decision support)

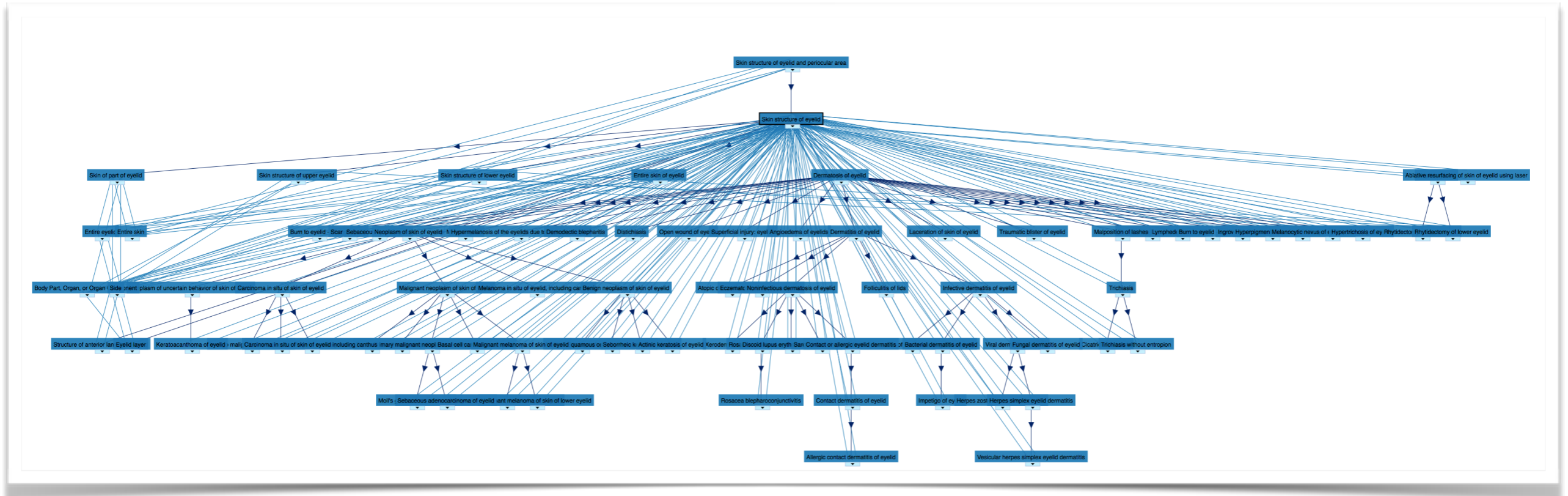
Essential for Accurate **ICD-10 (ICD-11) Coding**



Logic-Based

Skin Structure of Eyelid

(78 Concepts)



ISBN 978-3-16-148410-0



9 783161 484100

#1163

(credit to anon)

"Latin is a language,
dead as dead can be.
It killed the ancient Romans,
and now it's killing me."

latin-student-problems.tumblr.com

Where to Start?



COPYRIGHT © 2020 EZDERM, LLC – All Rights Reserved





The hardest thing to see is what
is in front of your eyes.

~ Johann Wolfgang von Goethe

AZ QUOTES

All diseases are disturbances at the cellular level.



Rudolph Virchow, 1858

9th Conf. int. Soc. geogr. Pathol., Leiden 1966
Path. Microbiol. 30: 826-827 (1967)

Columbia University, College of Physicians and Surgeons, New York, N.Y.

Systematized Nomenclature of Pathology

S. C. SOMMERS, New York, N.Y.

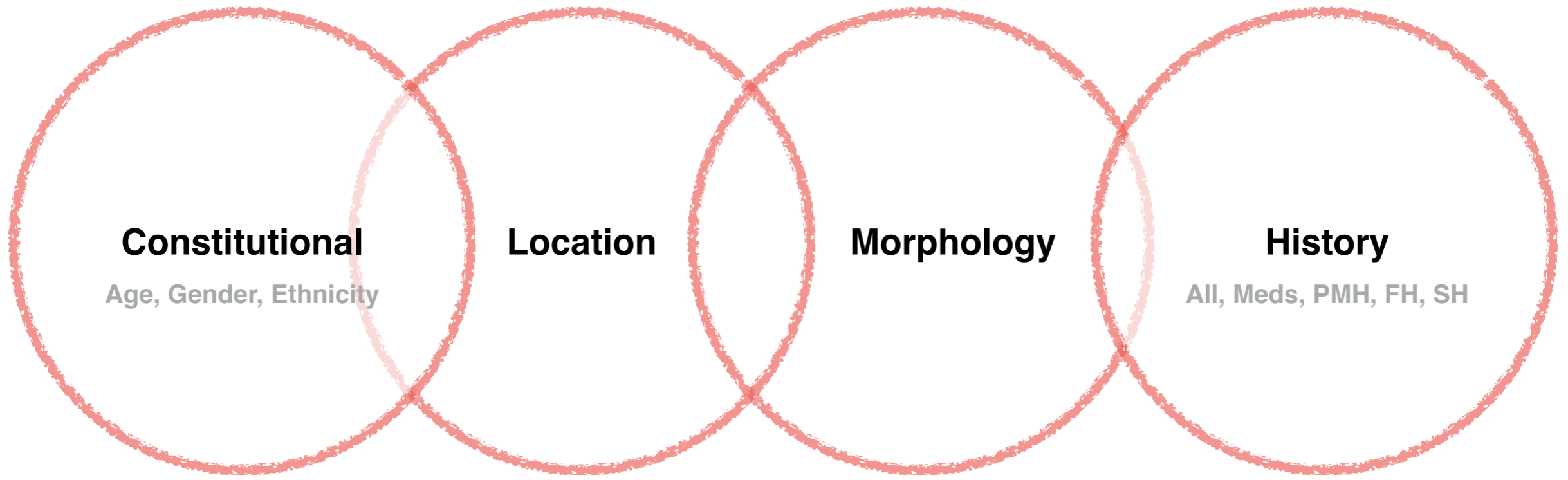
The Systematized Nomenclature of Pathology (SNOP) was developed for pathologists and other medical workers, to provide a convenient modern method for the storage and retrieval of labora-

The organization of SNOP involves four fields of information: Topography (T), the anatomical site; Morphology (M), the morbid anatomical lesion; Etiology (E), the causative agent; and Function (F), the pathophysiological change. Any field may be used alone, or any combination of fields may be employed. The topographic

Topography (T), the anatomical site; Morphology (M), the morbid anatomical lesion; Etiology (E), the causative agent; and Function (F), the pathophysiological change. Any field may be used alone, or any combination of fields may be employed. The topographic field exists in two forms: (1) a two-digit numerical system with a duodecimal base, permitting simplified assignments of anatomic sites, such as T43 for coronary artery; and (2) a compatible expanded four-digit system permitting more anatomical detail, for example T4311 for anterior descending branch of left coronary artery.

The Morphological field lists anatomic pathology terms in four digits, such as M5220 for arteriosclerosis. For convenience, when a morphologic diagnosis is site-specific, such as arteriolonephrosclerosis, the two-digit topographic code number is listed with it in the indexes, T-71 for kidney in this case. Closely related items

<https://www.karger.com/Article/PC>



Bays' Theorem

Dx & DDx

Treatment

Further Testing

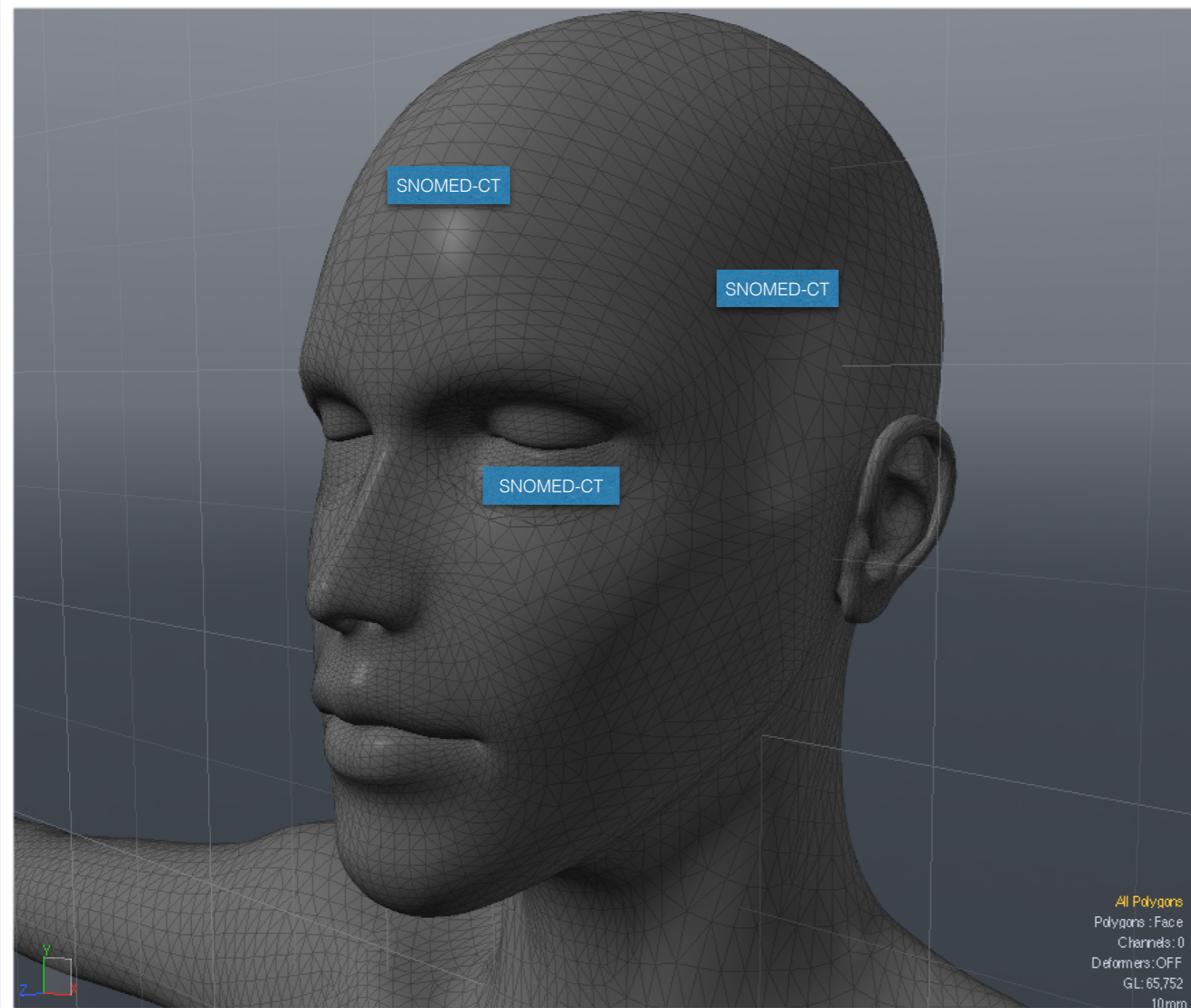
Location^{3D}



COPYRIGHT © 2020 EZDERM, LLC – All Rights Reserved



3D Anatomical Human Model



75,000+ Polygons

38,000+ Vertices

2,000+ Anatomical Locations

Built in
Clinical Logic



COPYRIGHT © 2019 EZDERM, LLC – All Rights Reserved



SNOMED-CT Morphologies

44132006	abscess
767376003	lentigo
1312007	guttate
64305001	wheal

SNOMED-CT Anatomical Locations - Disorders

2	Snomed-ID	ICD-10	Condition	Condition (Fully specified name)	Questions	Associated Morphology
3	399992009	L26	Erythroderma (Generalized Exfoliative Dermatitis)	Erythroderma		excoriated, erythematous, scaly, wide-spread, patch
4	254725004	C44	Apocrine Hidrocystoma	Apocrine cystadenoma		red, soft, translucent, dome-shaped, movable, tense, black, shiny, nodule, papule, blue
5	109769000		Necrotizing Sialometaplasia	Necrotizing Sialometaplasia		bilateral, ulcerated, unilateral, tumor
6	402415001		Schnitzler Syndrome	Schnitzler Syndrome		papule, plaque
7	200722003	L98.0	Pyogenic granuloma	Pyogenic granuloma (disorder)	morphologic abnormality exists too RESOLVED-remains Disorder	red, ulcerated, pedunculated, shiny, nodule, papule
8	238706002		Laugier-Hunziker Syndrome	Laugier-Hunziker Syndrome		smooth, hyperpigmented, brown, black, well-defined-border, macule
9	4749004		Nasopalatine Duct Cyst	Naso-palatine duct cyst		translucent, dome-shaped, blue, fistula

History



History Elements & Synonyms

Cancel HPI - Rash + - ? ○ Done

Onset Duration: ○

Timing

+

Context Related to Conditions (PMH) Options

<input checked="" type="radio"/> Actinic keratosis	<input checked="" type="radio"/> Allergic reaction to animal
<input type="radio"/> Allergic reaction to drug	<input type="radio"/> Allergic rhinitis due to animals
<input type="radio"/> Allergic rhinitis due to pollen	<input type="radio"/> Allergy to animal hair
<input type="radio"/> Asthma	<input checked="" type="radio"/> Atopic dermatitis
	<input type="radio"/> Crohn's disease
	<input type="radio"/> Diabetes mellitus
	<input type="radio"/> Disorder of thyroid gland
	<input type="radio"/> Environment contains animals
	<input type="radio"/> Foreign travel history finding
	<input type="radio"/> HIV positive
	<input type="radio"/> Herpes labialis
	<input type="radio"/> Herpes zoster
	<input type="radio"/> Hospital patient
	<input type="radio"/> Hypothyroidism
	<input type="radio"/> Insect bite
	<input type="radio"/> Lives in a nursing home
	<input type="radio"/> Low nickel diet
	<input checked="" type="radio"/> Malignant melanoma
	<input type="radio"/> Nut-free diet
	<input type="radio"/> Psoriasis
	<input type="radio"/> Rheumatoid arthritis
	<input type="radio"/> Sickness in the family
	<input type="radio"/> Ulcerative colitis
	+

< **SYNONYMS...**

- Airway hyperreactivity**
- Asthma**
- Asthmatic**
- BHR - Bronchial hyperreactivity**
- Bronchial asthma**
- Bronchial hyperreactivity**
- Bronchial hyperresponsiveness**
- Bronchial hypersensitivity**

Kidney disease

Long stay hospital inpatient

Lupus erythematosus

Non-Hodgkin's lymphoma (clinical)

Previous multiple hospital admissions

Released from prison

Seasonal allergic conjunctivitis


Travel abroad

Viral hepatitis C

Medications




TNM Cancer Staging

Conditions	
Diagnosis	LM - Lentigo maligna  >
Presence	Yes >
Onset Date	Sep 23, 2013 >
TNM Cancer Staging	Stage 0 - TisN0M0 >

Automated Coding

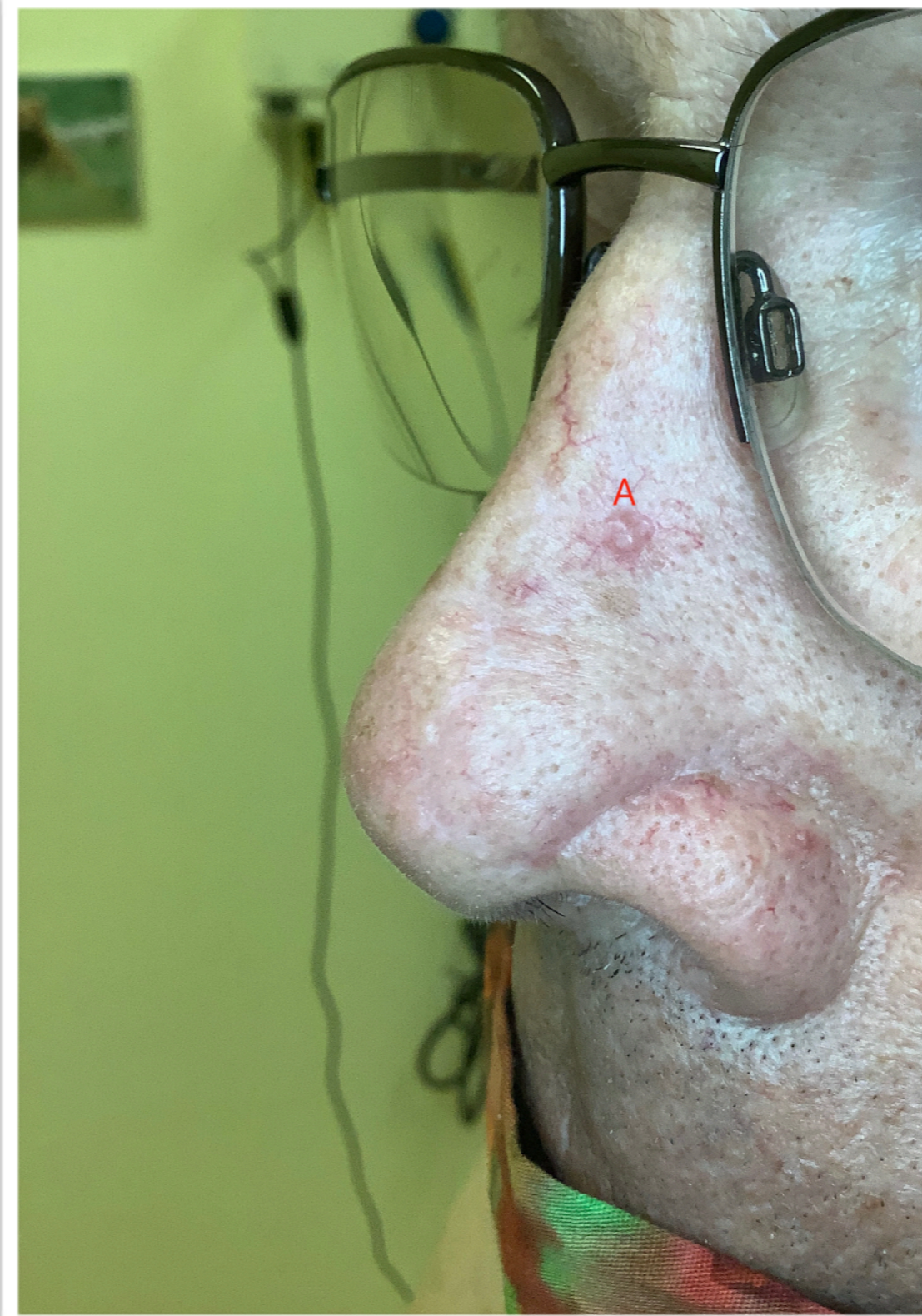



**Any sufficiently advanced technology
is
indistinguishable from magic.**

Third Law of Prediction - Arthur C. Clarke

Examples



DIAGNOSIS:

Skin biopsy, nose left nasal sidewall

NODULAR BASAL CELL CARCINOMA WITH SCLEROSIS; EXTENDING TO PERIPHERAL AND DEEP MARGINS

[-] Concept: [403913006] Morpheic basal cell carcinoma

[-] **Tree Positions (152)**

[-] Morpheic basal cell carcinoma [Context 1]

[-] [SNOMED CT Concept](#)

[-] [Clinical finding](#)

[-] [Finding by site](#)

[-] [General finding of soft tissue](#)

[-] [Disorder of soft tissue](#)

[-] [Disorder of skin and/or subcutaneous tissue](#)

[-] [Disorder of skin](#)

[-] [Skin lesion](#)

[-] [Neoplasm of skin](#)

[-] [Malignant neoplasm of skin](#)

[-] [Malignant epithelial neoplasm of skin](#)

[-] [Malignant basal cell neoplasm of skin](#)

[-] [Basal cell carcinoma of skin](#)

[Basal cell carcinoma - infiltrative](#)

[-] Concept: [403913006] Morpheic basal cell carcinoma

Outstanding (A)

Intermediate

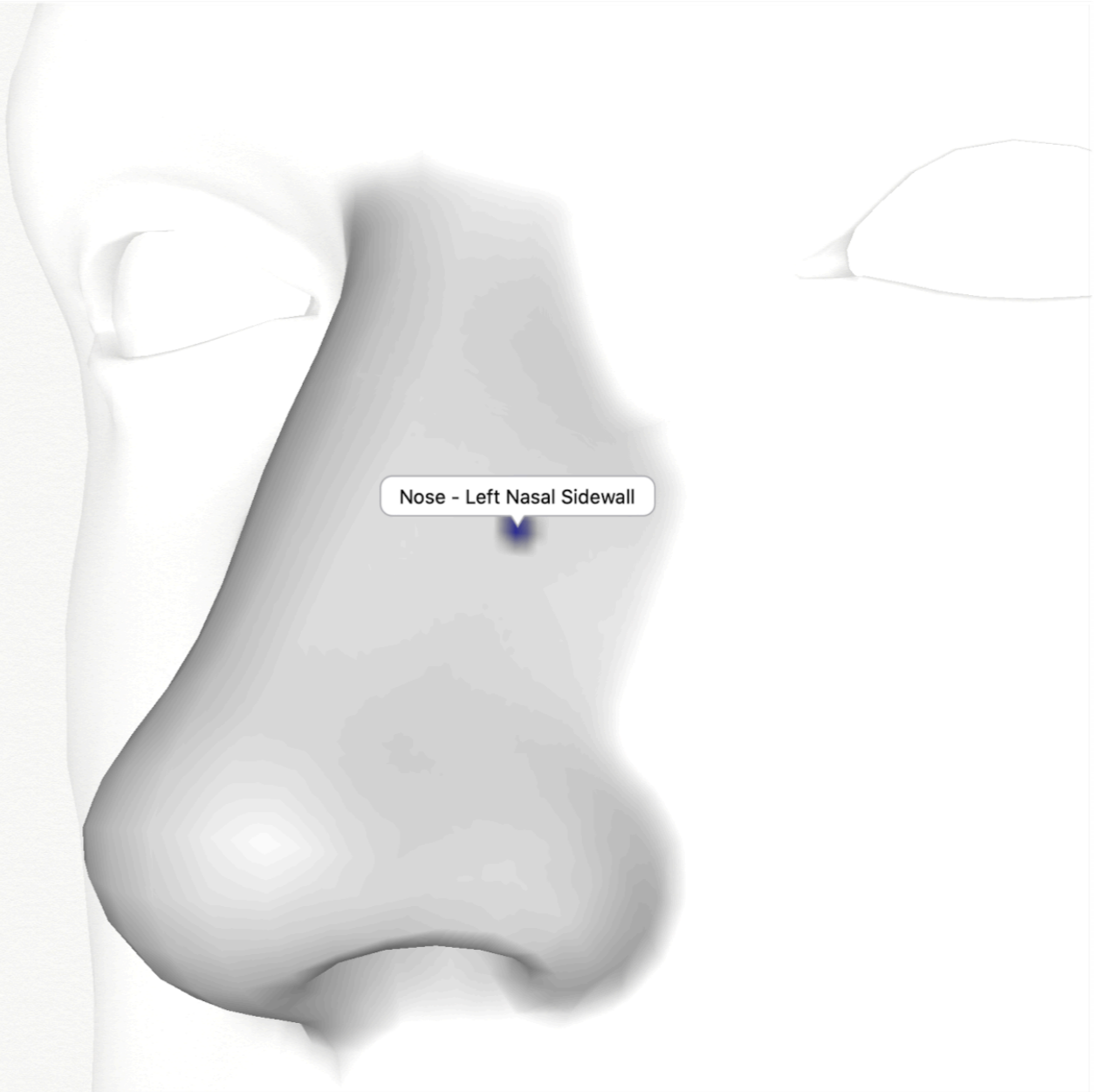
Actinic keratosis
Distal Segment of Posterior Right Forearm
Tuesday, December 24, 2019

Basal cell carcinoma of skin

Morpheic basal cell carcinoma ✓
Nose - Left Nasal Sidewall
Tuesday, May 26, 2020

Basal cell carcinoma of skin
Right Region of Occipital Scalp
Tuesday, September 11, 2018

Album
Biopsy
Hide Tags
Body



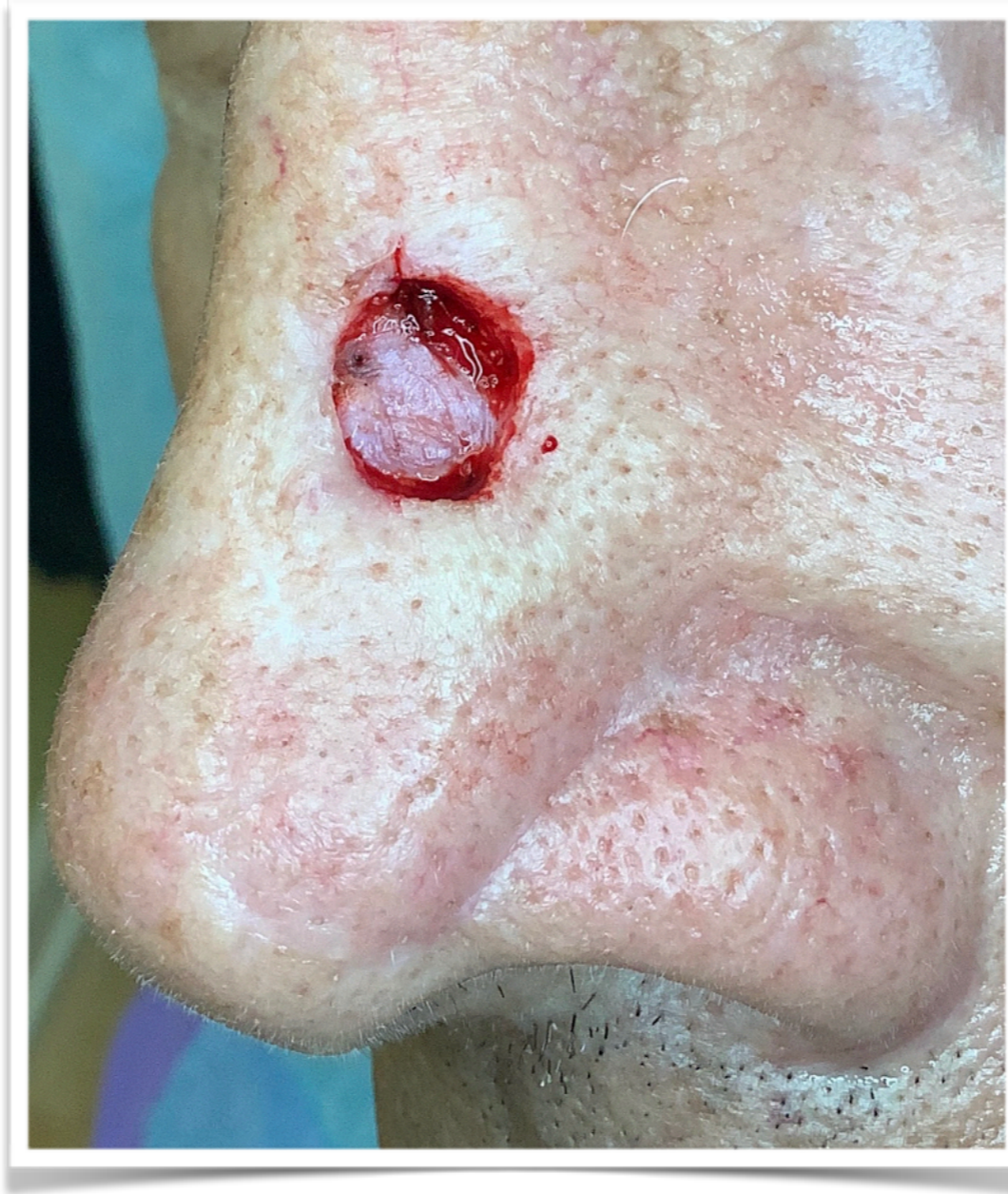Neoplasm of uncertain behavior of skin
Wednesday, May 13, 2020

Morpheic basal cell carcinoma
Thursday, May 14, 2020

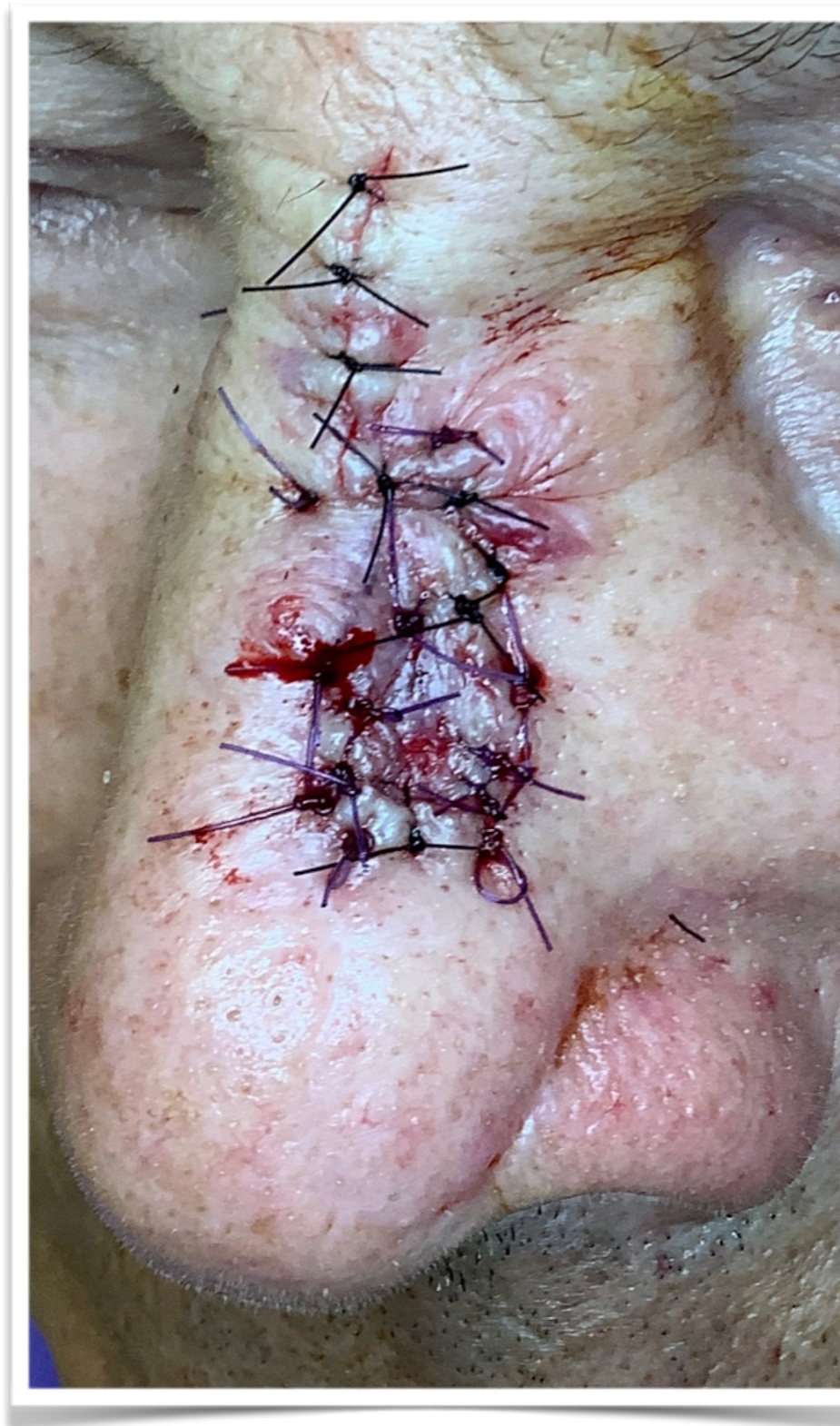Morpheic basal cell carcinoma
Tuesday, May 26, 2020

Outstanding Planned Problems

Mohs Micrographic Surgery



Bilobed Transposition Flap



Automated Coding and Billing

[-] Concept: [403913006] Morpheic basal cell carcinoma

Nose - Left Nasal Sidewall

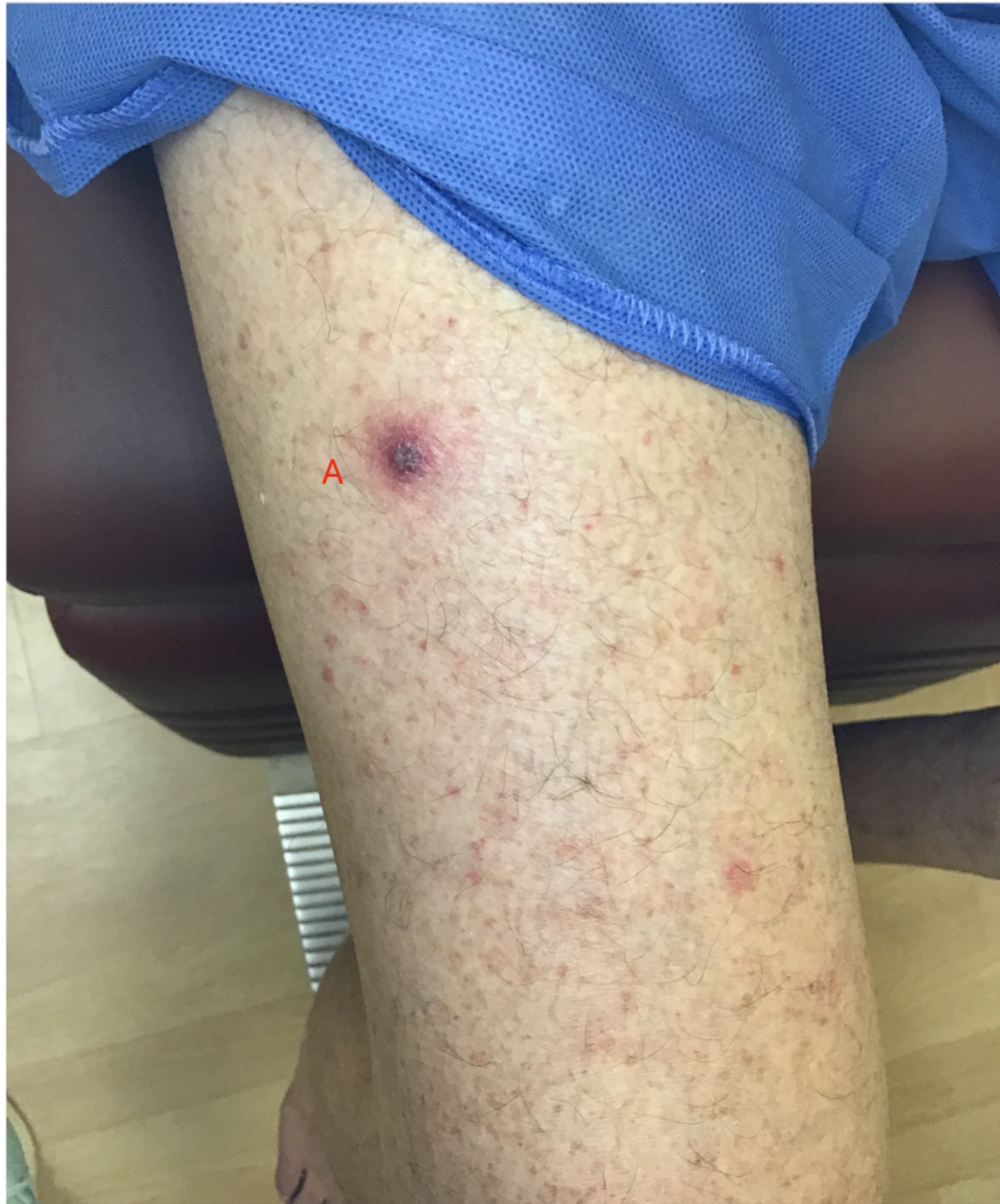BILLING CODES

C44.311 - Basal cell carcinoma of skin of nose

PROCEDURES

14060 - ADJT TIS TRANSFR/REARRGMT E/N/E/L DFCT 10 SQ CM/<
1 Unit(s)
ICD(s): C44.311

17311 - MOHS MICROGRAPHIC H/N/H/F/G 1ST STAGE 5 BLOCKS
1 Unit(s)
ICD(s): C44.311



Collected: 06/25/19

Received: 06/25/19

Reported: 06/28/19



DERMATOPATHOLOGY REPORT
PHOTOMICROGRAPH(S)

RESULTS

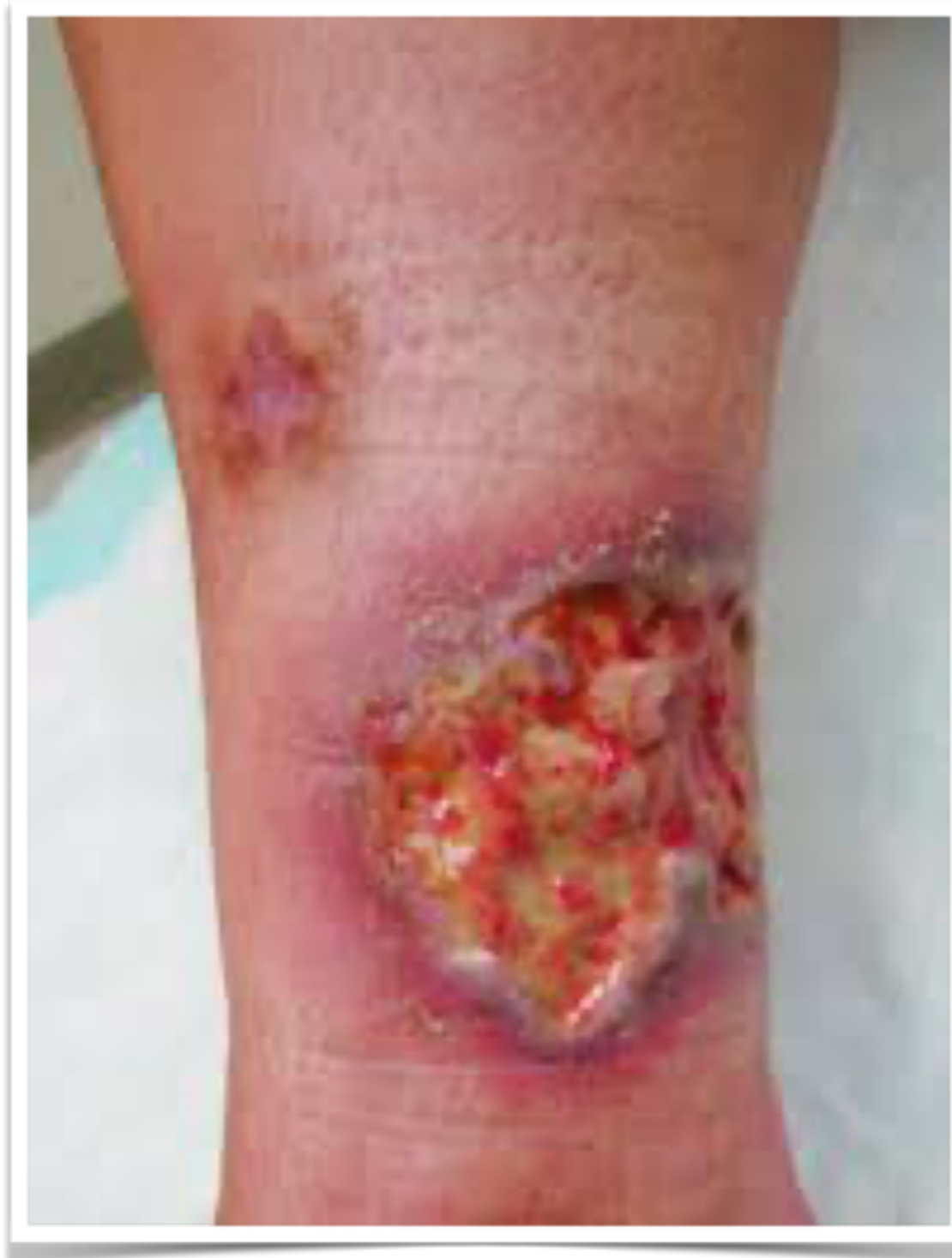DIAGNOSIS:

SKIN BIOPSY, RIGHT UPPER ARM -

ULCERATION AND SUPPURATIVE INFLAMMATION.

Note: Immunoperoxidase stains are negative for HSV1, HSV1, VZV and p63. Immunoperoxidase for CD30 highlights scattered cells. The PAS stain is negative for fungi. Deeper sections performed. The differential diagnosis could include an ulcerated dermal hypersensitivity reaction to an arthropod bite or lesion of pyoderma gangrenosum. If the lesion persists or fails to resolve, additional sampling with

Pyoderma Gangrenosum?



DIAGNOSIS:

Skin biopsy, central region of right anterior thigh

**NECROTIZING GRANULOMATOUS DERMATITIS WITH SMALL VESSEL VASCULITIS, HEMORRHAGE, EPIDERMAL AND FOLLICULAR NECROSIS, POLYMORPHOUS DERMAL INFILTRATE CONTAINING FREQUENT EOSINOPHILS AND DERMAL EDEMA
SEE COMMENT**

COMMENT:

THESE FINDINGS ARE NOT ENTIRELY SPECIFIC, HOWEVER, MOST LIKELY REPRESENT A CUTANEOUS MANIFESTATION OF CROHN'S DISEASE (e.g., METASTATIC CUTANEOUS CROHN'S DISEASE), ALTHOUGH, AN UNUSUAL HEMORRHAGIC ARTHROPOD ASSAULT CANNOT BE ENTIRELY EXCLUDED. THE VASCULITIS NOTED MOST LIKELY REPRESENTS A SECONDARY COMPONENT ASSOCIATED WITH THE NECROTIZING GRANULOMATOUS INFLAMMATION, NEVERTHELESS, A FULL VASCULITIS WORK UP SHOULD BE CONSIDERED. SPECIAL STAINS (GRAM, PAS, AFB) ARE NEGATIVE, THEREBY, MILITATING AGAINST A PECULIAR INFECTIOUS PROCESS

[-] Concept: [402378006] Metastatic Crohn's disease of skin

[-] **Tree Positions (18)**

[-] Metastatic Crohn's disease of skin [Context 1]

[-] SNOMED CT Concept

[-] Clinical finding

[-] Finding by site

[-] Disorder by body site

[-] Disorder of body system

[-] Inflammation of specific body systems

[-] Inflammation of skin and/or subcutaneous tissue

[-] Granulomatous disorder of the skin and subcutaneous tissue

Crohn's disease of skin

Outstanding A

Granulomatous disorder of the skin and subcutaneous tissue

Metastatic Crohn disease of skin ✓
Central Region of Right Anterior Thigh
Wednesday, April 15, 2020

Metastatic Crohn's disease of skin
Central Region of Right Anterior Thigh
Thursday, December 5, 2019

Album

Biopsy

Accept

Hide Tags

Body

🔍 Outstanding	🕒 Planned	☰ Problems	Rash day, Dec 2, 2019	Metastatic Crohn disease of skin Wednesday, Dec 4, 2019	Metastatic Crohn disease of skin Monday, Dec 16, 2019	Metastatic Crohn disease of skin Wednesday, Apr 15, 2020
---	-------------------------------	--------------------------------	---------------------------------	---	---	--

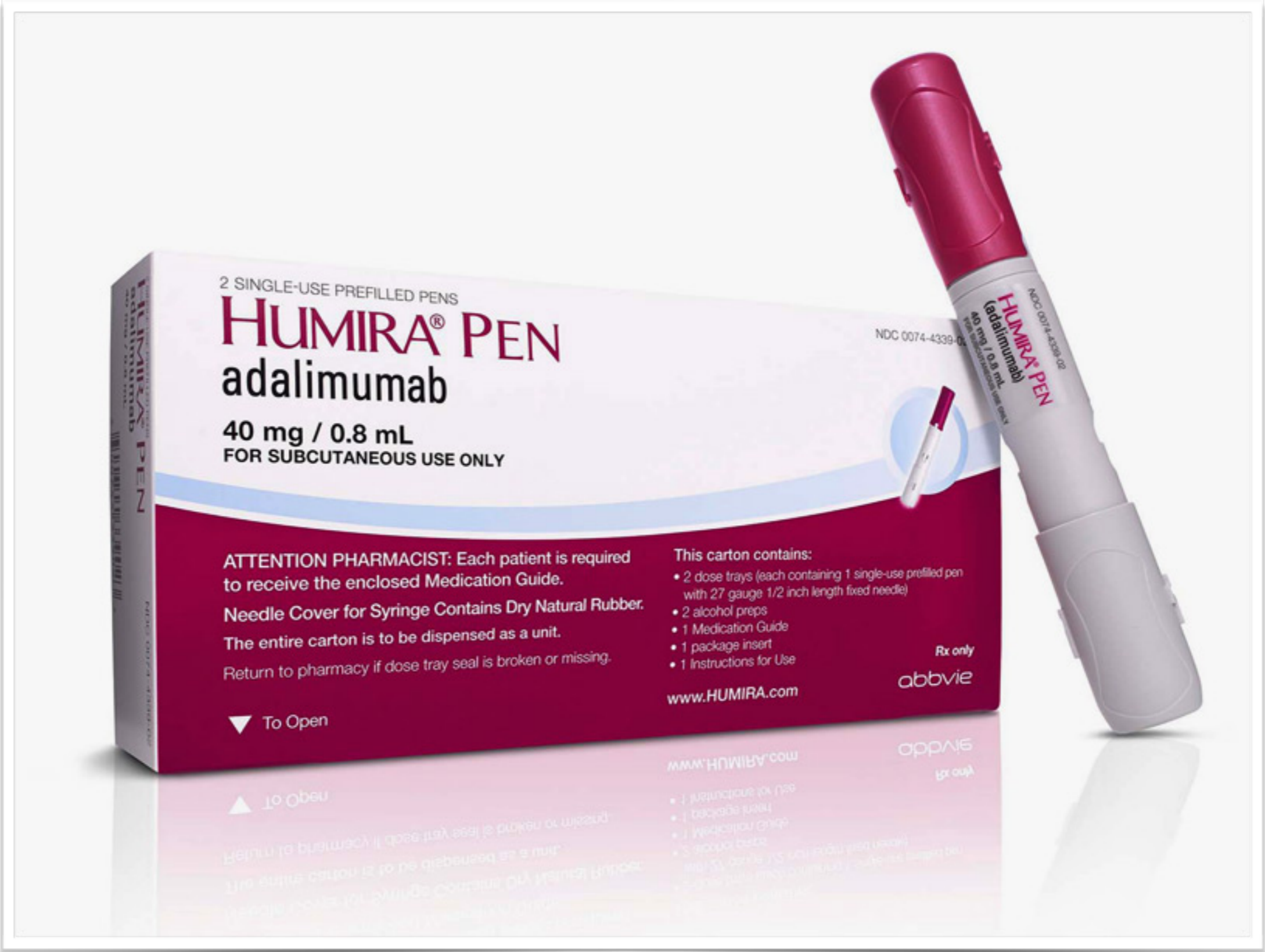CLINICAL—ALIMENTARY TRACT

Adalimumab Induces and Maintains Mucosal Healing in Patients With Crohn's Disease: Data From the EXTEND Trial

PAUL RUTGEERTS,* GERT VAN ASSCHE,* WILLIAM J. SANDBORN,[‡] DOUGLAS C. WOLF,[§] KAREL GEBOES,^{||} JEAN-FRÉDÉRIC COLOMBEL,[¶] WALTER REINISCH,[#] for the EXTEND Investigators, ASHISH KUMAR,** ANDREAS LAZAR,^{††} ANNE CAMEZ,^{††} KATHLEEN G. LOMAX,** PAUL F. POLLACK,** and GEERT D'HAENS^{§§.|||}

**Department of Gastro-Enterologie, University Hospital of Gasthuisberg, Leuven, Belgium; ‡University of California San Diego, La Jolla, California; §Atlanta Gastroenterology Associates, Atlanta, Georgia; ||Department of Pathology, University Hospital, KU Leuven, Leuven, Belgium; ¶Hôpital Claude Huriez, Centre Hospitalier Universitaire de Lille, Lille, France; #Medical University of Vienna, Vienna, Austria; **Abbott Laboratories, Abbott Park, Illinois; ††Abbott GmbH & Co. KG, Ludwigshafen, Germany; §§Academic Medical Centre, Amsterdam, The Netherlands; and |||Imelda GI Clinical Research Center, Department of Internal Medicine, Bonheiden, Belgium*

CLINICAL AT



2 SINGLE-USE PREFILLED PENS
HUMIRA® PEN
adalimumab

40 mg / 0.8 mL
FOR SUBCUTANEOUS USE ONLY

NDC 0074-4339-02

ATTENTION PHARMACIST: Each patient is required to receive the enclosed Medication Guide.
Needle Cover for Syringe Contains Dry Natural Rubber.
The entire carton is to be dispensed as a unit.
Return to pharmacy if dose tray seal is broken or missing.

- This carton contains:**
- 2 dose trays (each containing 1 single-use prefilled pen with 27 gauge 1/2 inch length fixed needle)
 - 2 alcohol preps
 - 1 Medication Guide
 - 1 package insert
 - 1 Instructions for Use

www.HUMIRA.com

Rx only
abbvie

▼ To Open



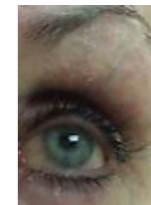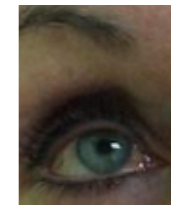
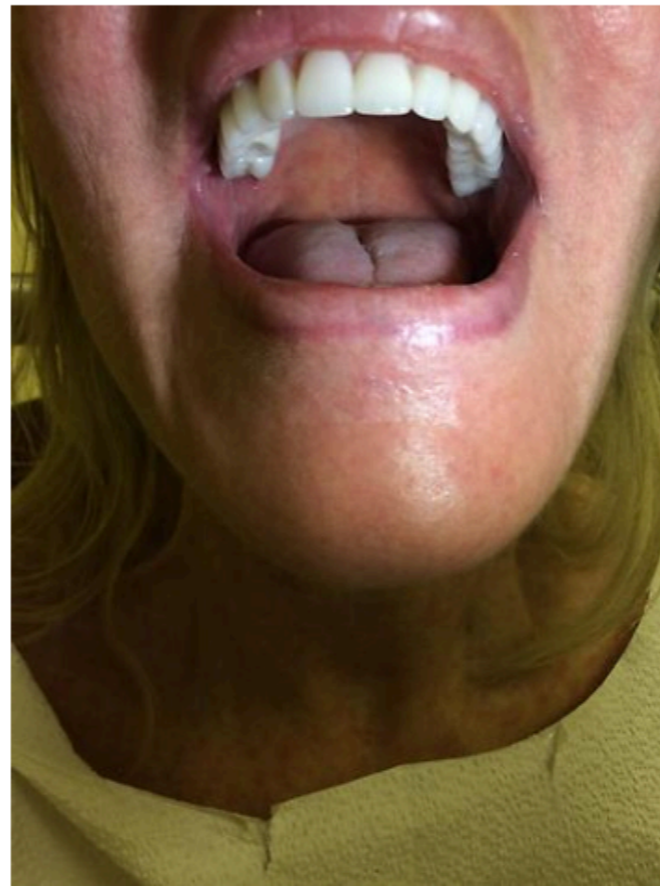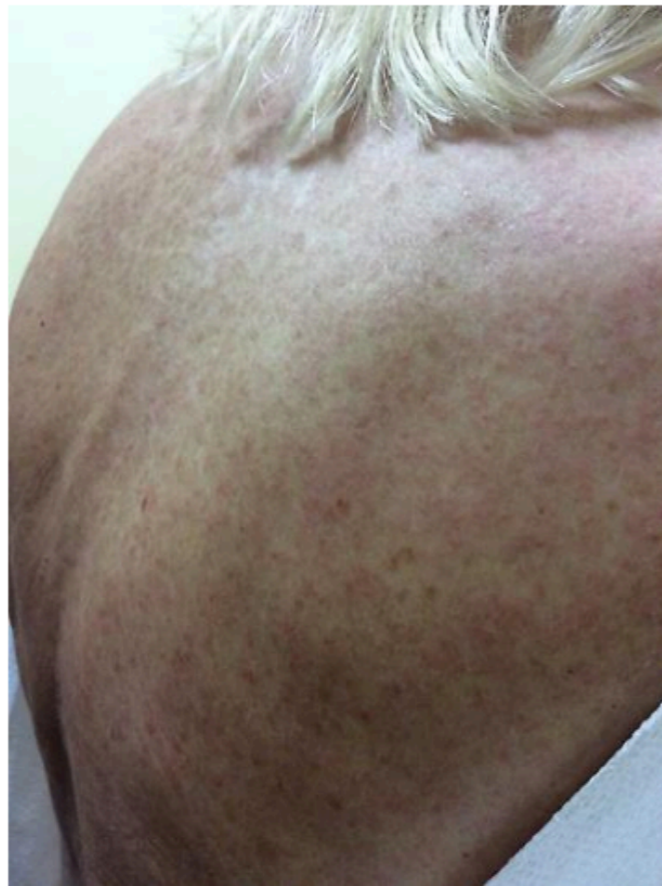COPYRIGHT © 2020 EZDERM, LLC – All Rights Reserved



Exanthem, Enanthem, Injected Conjunctivae

IMAGES

Rash



DIAGNOSES:

1. Skin biopsy, central region of left gluteal area
POLYMORPHOUS DERMATITIS WITH EOSINOPHILS
SEE COMMENT
2. Skin biopsy, central region of right gluteal area
INTERFACE DERMATITIS WITH POLYMORPHOUS DERMAL INFILTRATE
SEE COMMENT

COMMENTS:

PART 1 (central region of left gluteal area): **THE HISTOLOGIC FEATURES FAVOR A DIAGNOSIS OF DRUG ERUPTION BUT GIVEN THE CLINICAL CIRCUMSTANCES, THE POSSIBILITY OF AN UNUSUAL VIRAL INFECTION CANNOT BE EXCLUDED**

PART 2 (central region of right gluteal area): **THE HISTOLOGIC CHANGES FAVOR A DIAGNOSIS OF INTERFACE DRUG ERUPTION BUT GIVEN THE CLINICAL CIRCUMSTANCES, THE POSSIBILITY OF AN UNUSUAL VIRAL INFECTION CANNOT BE EXCLUDED**

HPI The patient is 65-year-old female who presents with the following complaint(s):

Rash (Chief Complaint): The complaint involves right lower extremity, pelvis, right cheek, right upper extremity, abdomen, left lower extremity, neck, forehead, left cheek, back, chest and left upper extremity. The patient reports bright redness and itching of skin. The severity is rated as moderate (Itching). Onset: 2 day(s). Modifying factors include daily multivitamin (currently not taking). The patient started the vitamins 3 days ago.

Two weeks ago (Sat, Oct 8, 2016), the patient went on a one week cruise and visited several islands in Spanish Caribbean. The patient did not see any sick contacts, did not have interaction with animals and does not remember being bitten by mosquitos. She was "excellent health" and did not have any skin findings until 2-3 days ago. The patient also reports starting Nutrilite Women's Pack MVI 3 days ago. She has stopped this yesterday.

Pertinent positive(s) include: muscle weakness. Pertinent negative(s) include the absence of: chill and cough.

The patient denies been pregnant.

No history of procedure.

Zika Virus NAA Comprehensive						
Zika Virus, NAA, Serum	Positive	Abnormal			Negative	02
Zika virus RNA detected.	Positive					
Zika Virus, NAA, Urine	Positive	Abnormal			Negative	02
Zika virus RNA detected.	Positive					
C-Reactive Protein, Quant	5.5	High	mg/L	0.0 - 4.9		01

[-] Concept: [3928002] Zika virus disease

[-] **Tree Positions (1)**

[-] Zika virus disease

[-] SNOMED CT Concept

[-] Clinical finding

[-] Disease

[-] Disorder due to infection

[-] Viral disease

Disease due to Flavivirus

Zika Virus

Problems (A)

Intermediate

Pigmented actinic keratosis (4)
Buccal Segment of Right Preauricular Cheek
Wednesday, July 5, 2017

Eruption

Rash (7)
Right Upper Arm
Monday, May 22, 2017

Viral exanthem (15)
Central Region of Right Gluteal Area
Monday, October 24, 2016

Viral exanthem
Monday, October 24, 2016

Hemangioma

Hemangioma (7)
Back
Monday, May 22, 2017

Viral disease

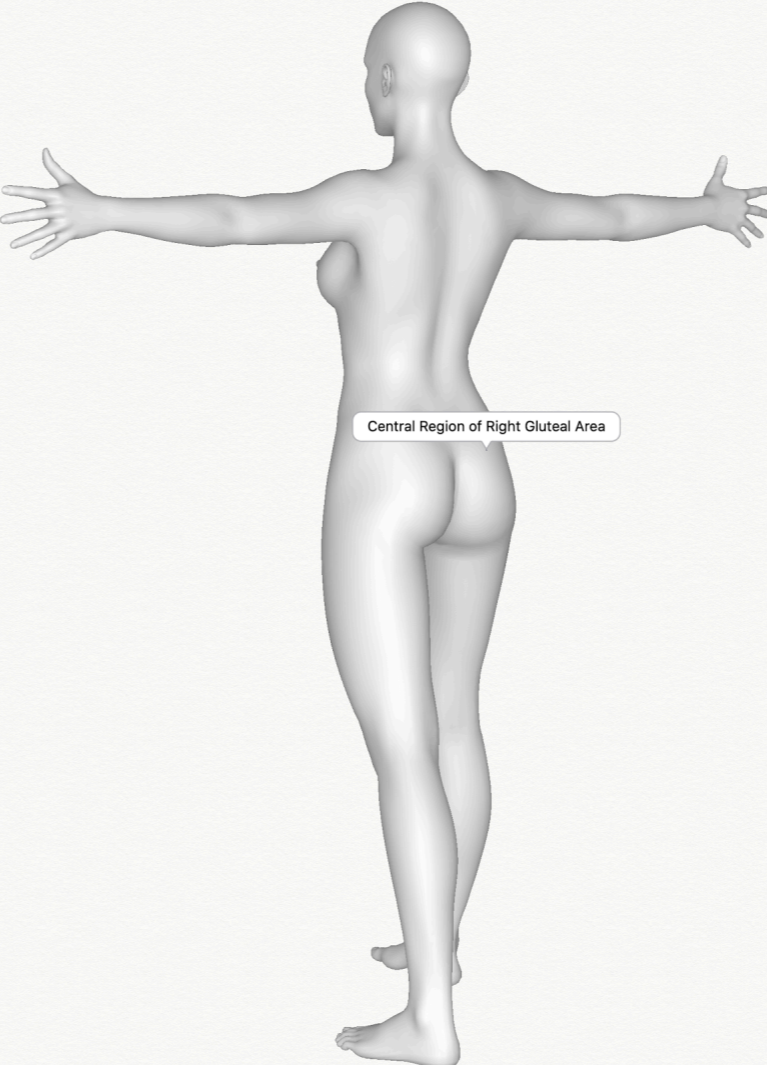
Zika virus disease
Central Region of Left Gluteal Area
Monday, October 31, 2016

Zika virus disease ✓
Central Region of Right Gluteal Area
Tuesday, October 25, 2016

Other

Leukopenia
Monday, October 24, 2016

Album
Biopsy
Accept
Hide Tags
Body



Central Region of Right Gluteal Area

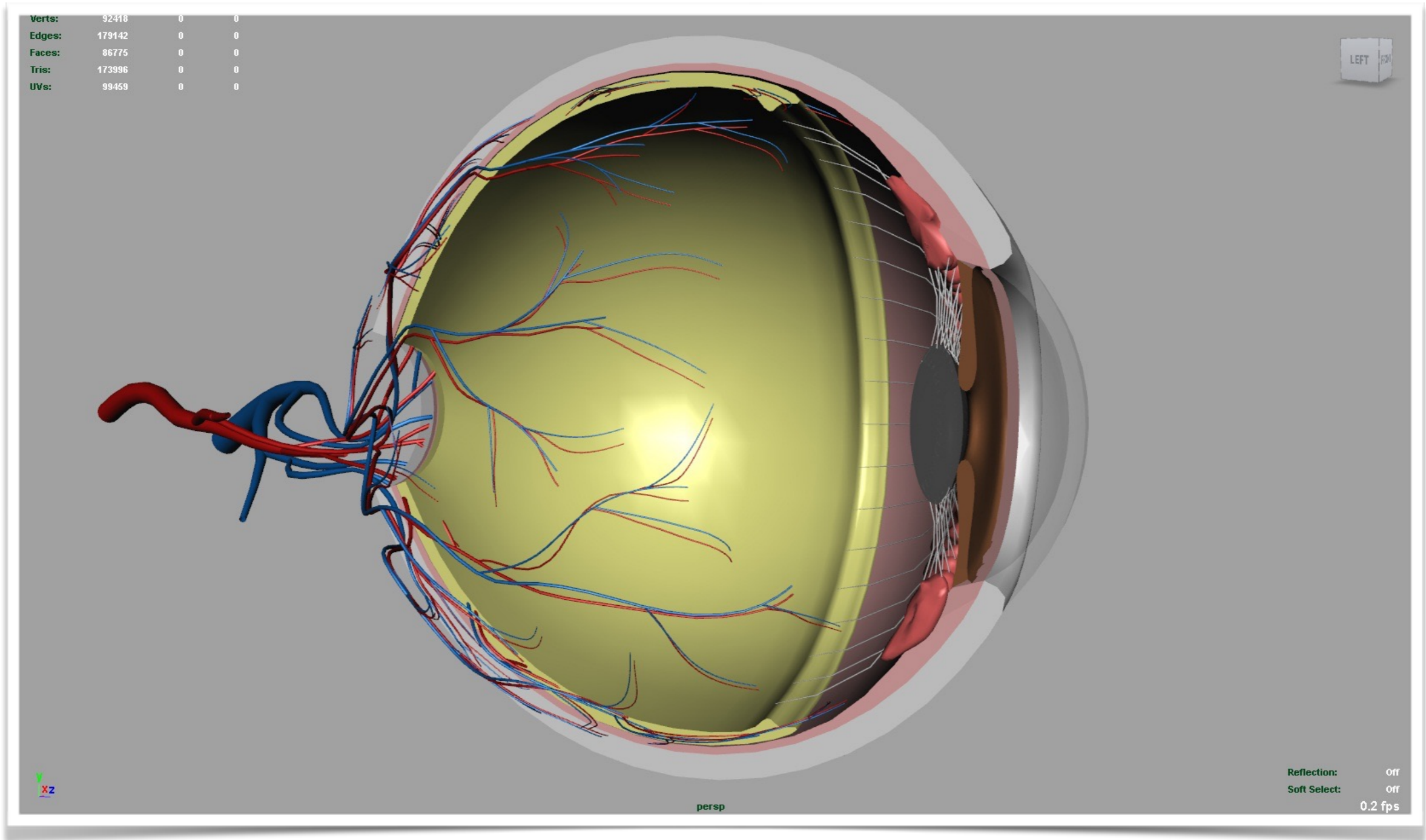
Outstanding Planned Problems

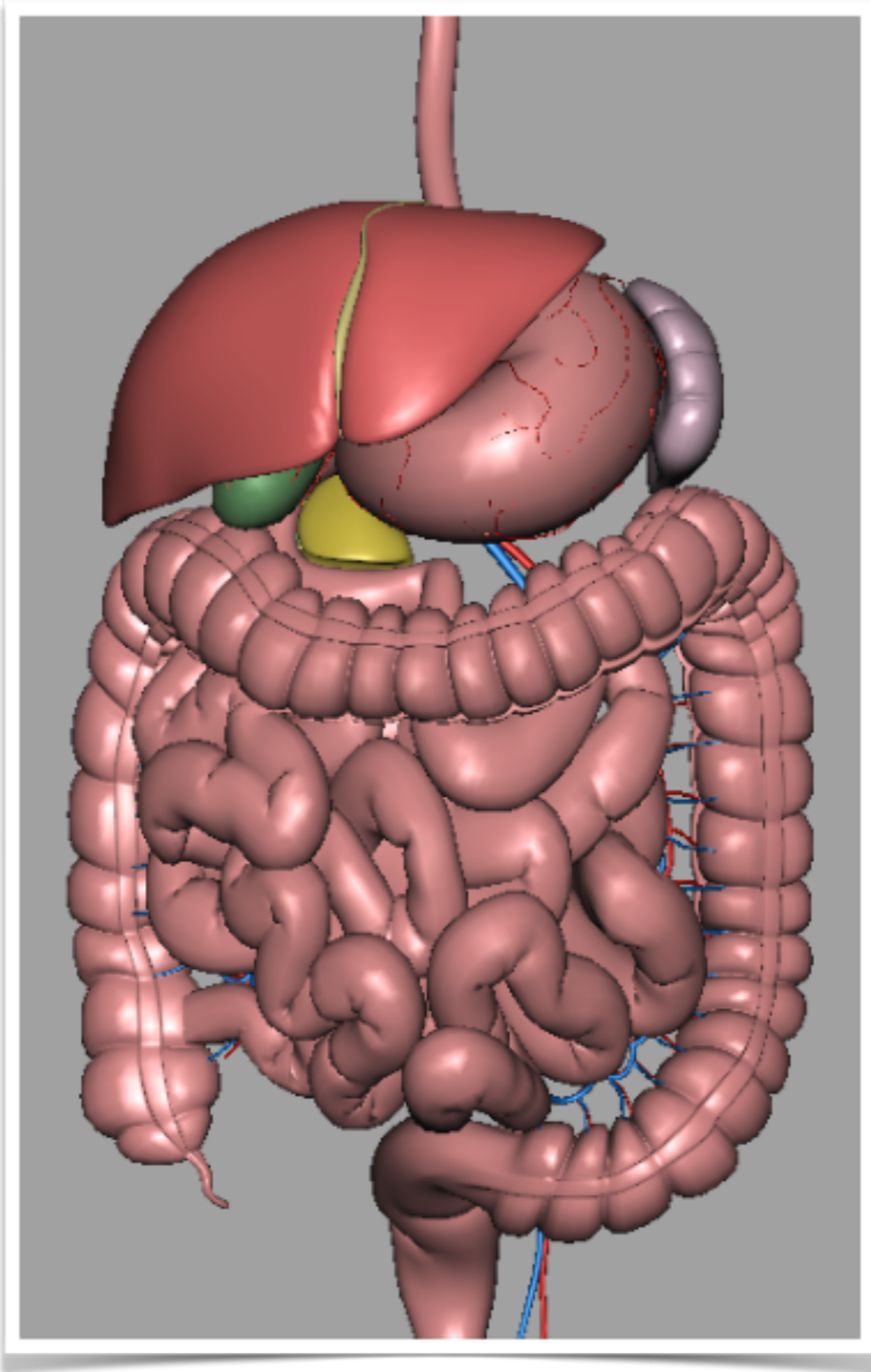
Rash
Friday, Oct 21, 2016

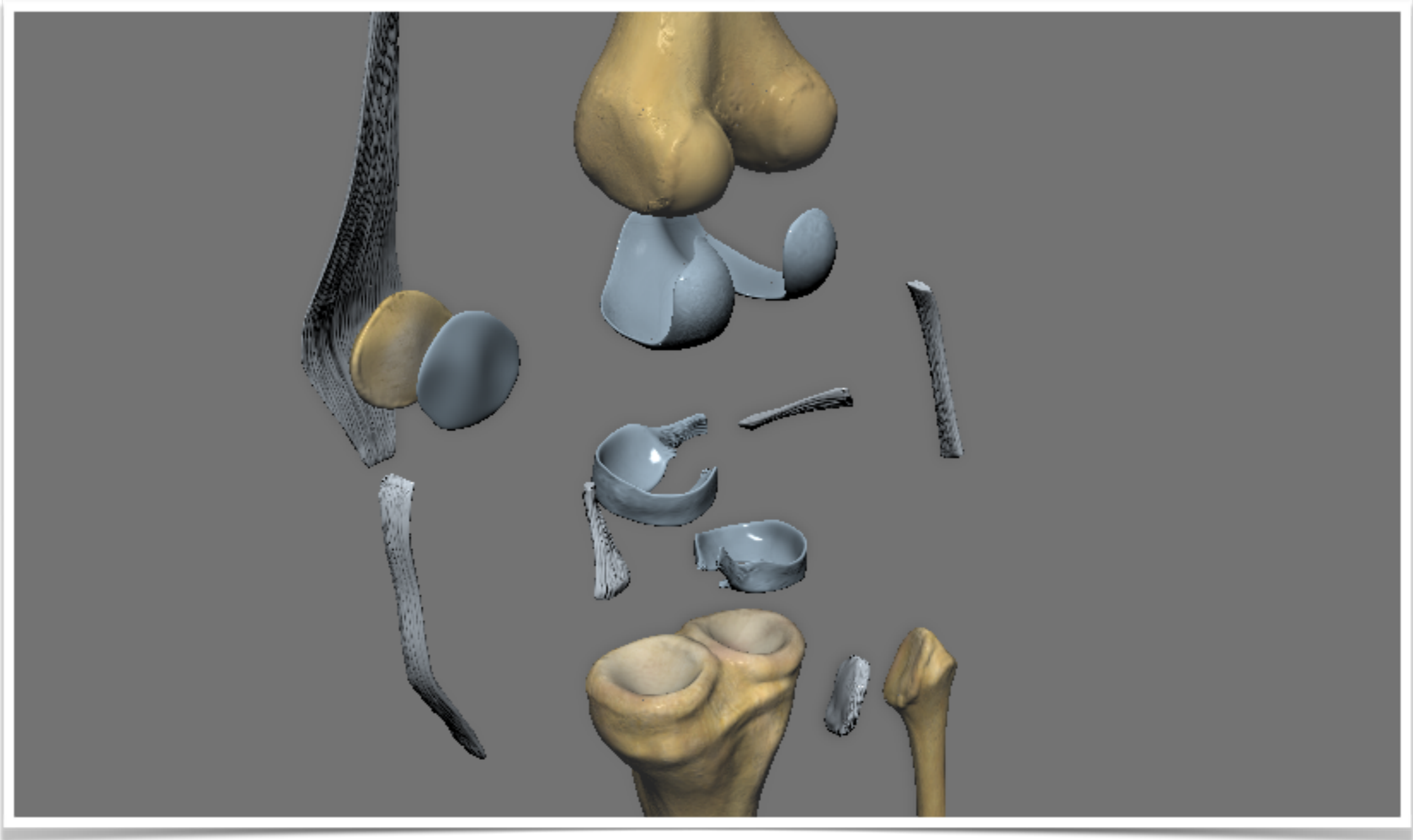
Zika virus disease
Tuesday, Oct 25, 2016

EZDERM Concept is Universal



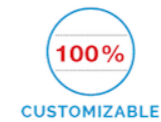





A Simply Smarter Electronic Health Record

Always A Dimension Above the Competition



All diseases are disturbances at the cellular level.



Rudolph Virchow, 1858



Roger A. Cote, MD, FACMI



COPYRIGHT © 2020 EZDERM, LLC – All Rights Reserved



Renaissance of HealthCARE



The Doctor - Sir Samuel Luke Fildes (1887)



ONE

POWERFUL SYSTEM



COPYRIGHT © 2019 EZDERM, LLC – All Rights Reserved





ONE

POWERFUL SYSTEM



COPYRIGHT © 2019 EZDERM, LLC – All Rights Reserved





ONE

POWERFUL SYSTEM



COPYRIGHT © 2019 EZDERM, LLC – All Rights Reserved

